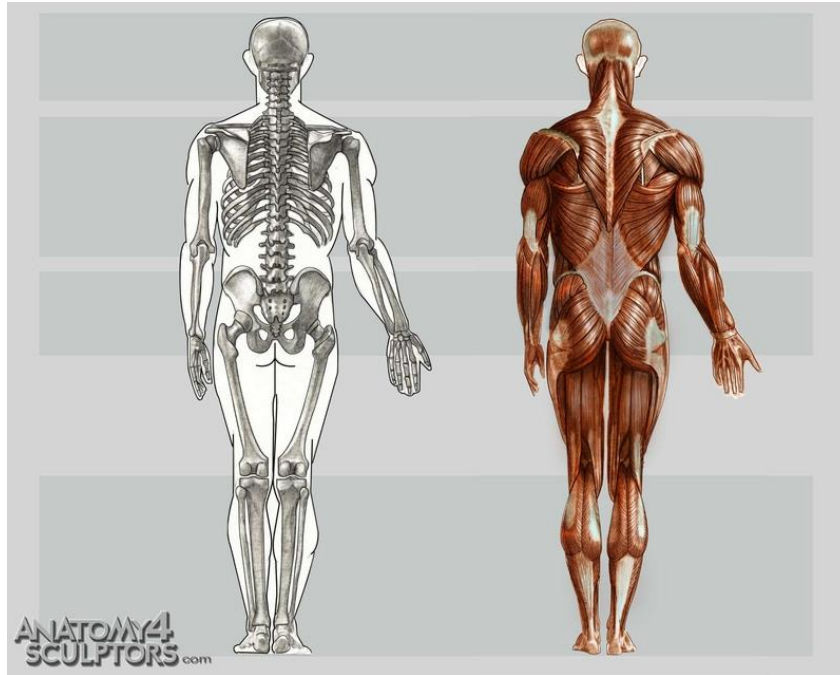

AM30085

**L3 AWARD IN ANATOMY &
PHYSIOLOGY**

ANATOMY & PHYSIOLOGY

TRAINING MANUAL

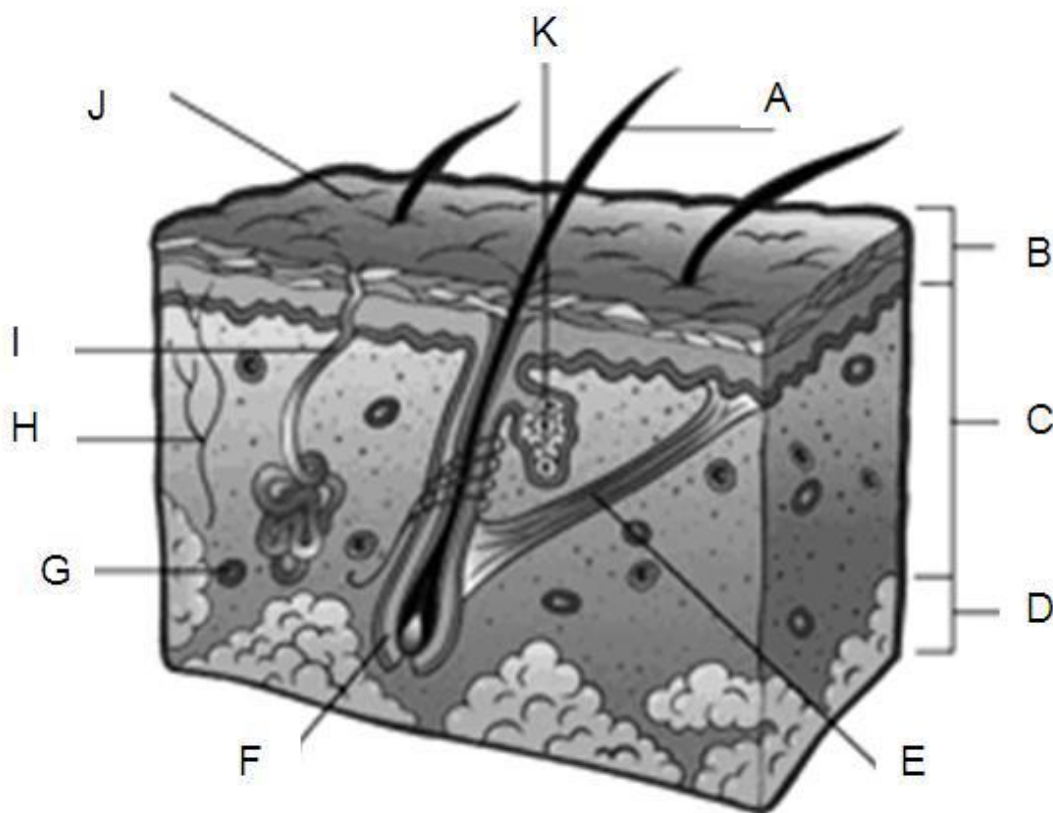
CONTENTS:

1.	Skin – Integumentary system
2.	Hair – Integumentary system

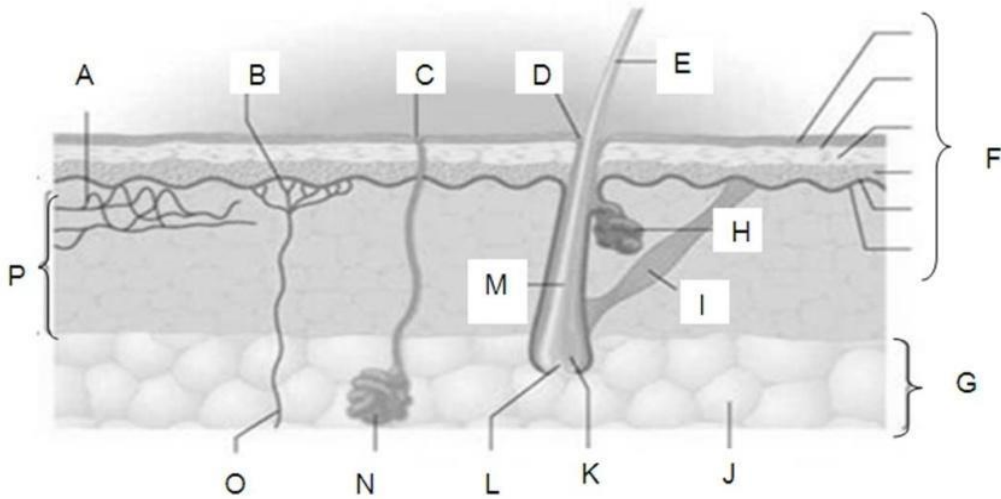
3.	Nails – Integumentary system
4.	Skeletal system
5.	Muscular system
6.	Nervous system
7.	Endocrine system
8.	Respiratory system
9.	Cardiovascular system
10.	Lymphatic system
11.	Digestive system
12.	Career pathways

SKIN

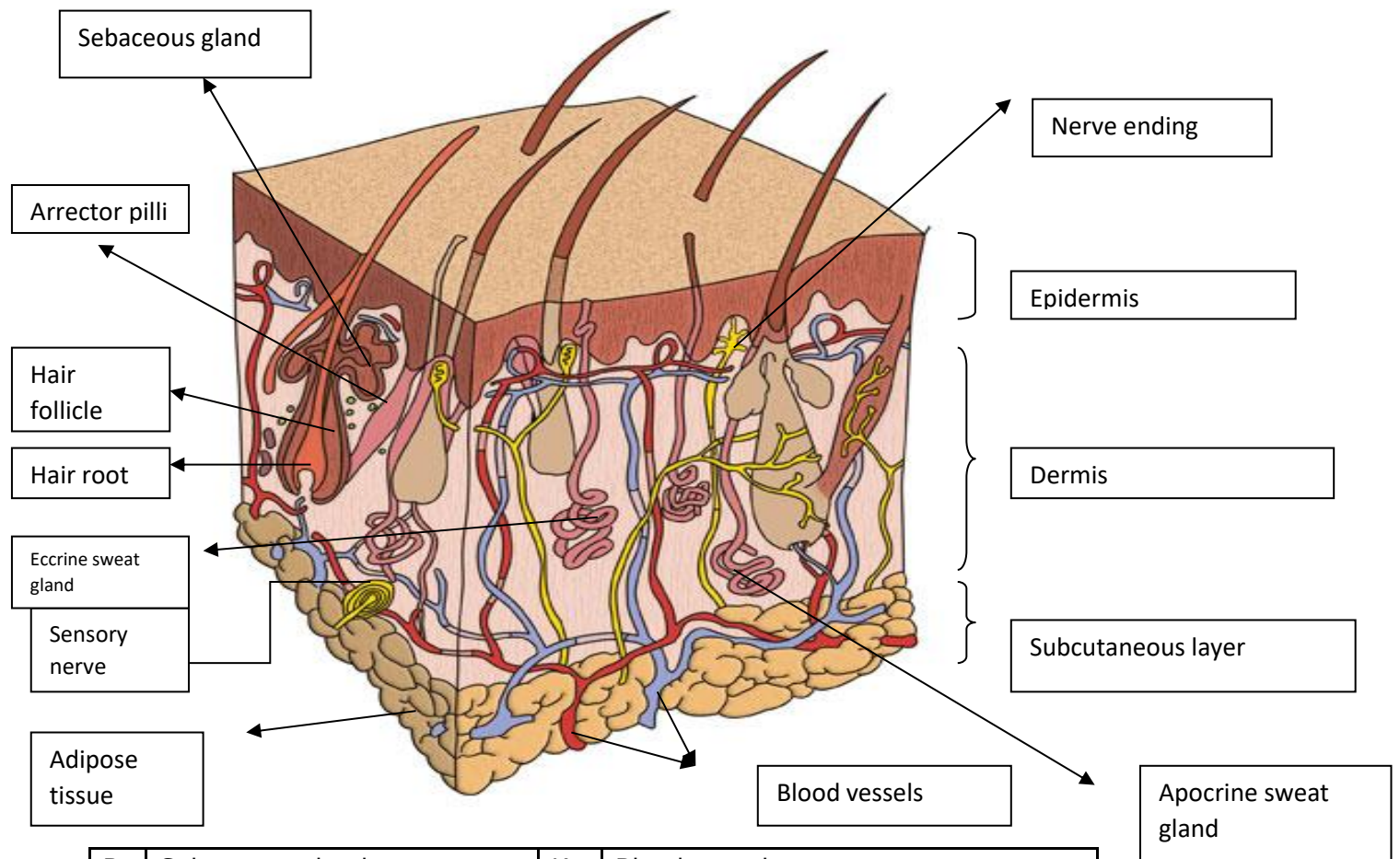
Structure of the skin



K	Sebaceous Gland
A	Hair shaft
B	Epidermis
C	Dermis
D	Subcutaneous layer
E	Arrector pili muscle
F	Hair follicle
G	Blood vessels
H	Nerve endings
I	Sweat gland
J	Pore



A	Blood vessels	I	Arrector pili muscle
B	Nerve endings	J	Adipose tissue (fat cells)
C	Sweat pore	K	Hair bulb
D	Hair follicle	L	Dermal papilla
E	Hair shaft	M	Hair root
F	Epidermis	N	Sweat gland
G	Subcutaneous layer	O	Nerve fibres
H	Sebaceous gland	P	Dermis



B	Sebaceous gland	K	Blood vessel
C	Arrector pili muscle	M	Nerve ending
F	Hair follicle	A	Epidermis
I	Hair root	D	Dermis
G	Eccrine sweat gland	E	Subcutaneous layer
H	Sensory nerve	J	Apocrine sweat gland
L	Adipose tissue		

Give picture – exam – revision test.

The skin is the largest organ of the body and forms part of the integumentary system along with the hair and nails.

- The skin is made up of two distinct layers, including the uppermost epidermis and the deeper dermis.

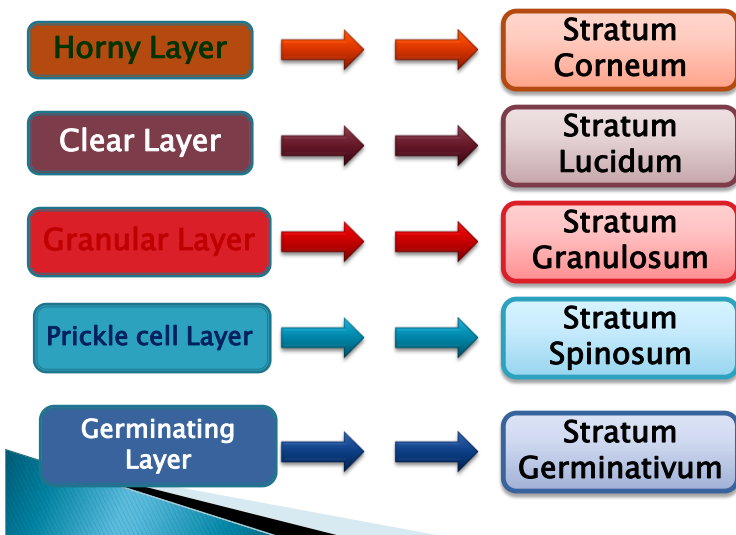
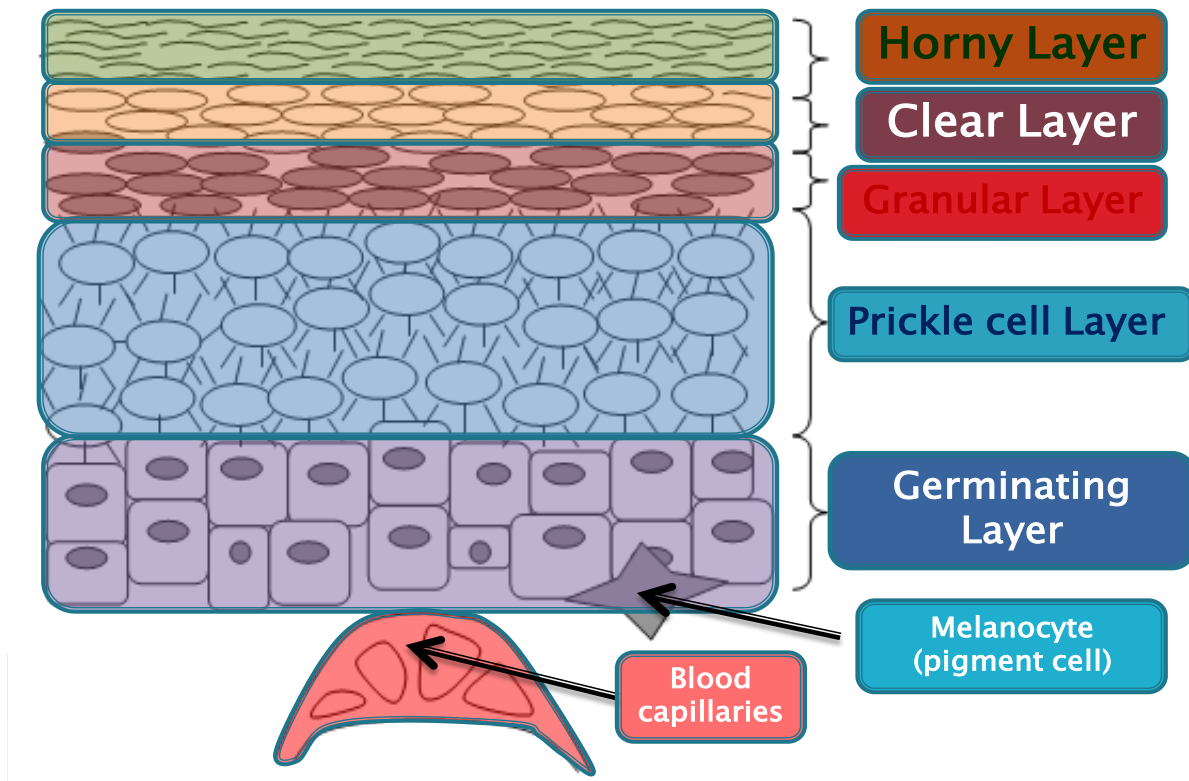
- Lying directly below the dermis is the subcutaneous layer where the body stores fat.
- Finally, the muscles and bones of the body lay below the subcutaneous layer.
- These layers of muscles, bones and fat form a protective barrier for the vital organs of the body e.g. Heart and lungs etc.

EPIDERMIS

This is outermost layer of the skin, which is formed from 5 distinct layers of cells that form stratified epithelial tissue. The cells are able to reproduce themselves in the lower layers and then continuously push their way to the surface, changing as they reach each new layer until they are shed from the body in a process known as exfoliation or desquamation.

EPIDERMIS – Key points

- Forms the uppermost portions of the skin.
- Forms a protective outer covering for the body.
- Formed from stratified squamous epithelial tissue.
- Made from 5 distinct layers.
- Traditionally the layers of the skin are called by their Latin names in reference books, although we commonly refer to them with their English description, it wise to be familiar with both terms.



Stratum Germinativum - Germinating Layer

- Connects with the dermis.
- Contains one row of cells that are able to reproduce by a process of simple cell division called mitosis.
- Contains cells called keratinocytes, which produce a protein called keratin.

- Contains cells called melanocytes, responsible for the formation of natural colour pigment called melanin.
- Nails develop from this layer of the skin.
- As new cells form, old cells are pushed up to form the stratum spinosum.

Stratum Spinosum – Prickle cell layer

- Contains approximately ten rows of cells.
- Reproduction of cells continues to take place in the lower rows of cells.
- Cells are starting to harden and become spiky and prickly through a process called keratinisation.
- As new cells continue to be produced, old cells are pushed upwards to form the stratum granulosum.

Stratum granulosum – Granular layer

- Contains approximately three rows of cells.
- Keratinisation becomes complete as the cells are filled with keratin.
- Cells are now dead and become flat and hard and granule-like.
- A yellow pigment called carotene is found in this layer.
- As new cells continue to be produced the old cells are pushed upwards into the stratum lucidum.

Stratum Lucidum – Clear Layer

- Contains approximately three rows of cells.
- The cells of this layer become clear and transparent.
- The cells form a waterproof layer that is thickest on the soles of the feet and the palms of the hands.
- As new cells continue to be produced, old cells are pushed upwards to form the stratum corneum.

Stratum Corneum – Horny layer

- Contains approximately twenty rows of cells.
- The cells of this layer provide the visual appearance of the skin.
- As the new cells in the lower layers of the epidermis continue to be produced, the old cells are naturally shed, exfoliated or desquamated from the skin.

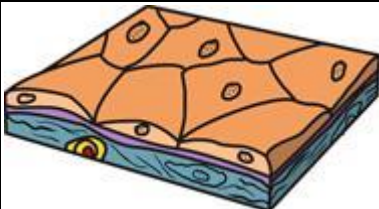
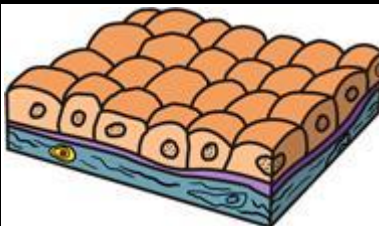
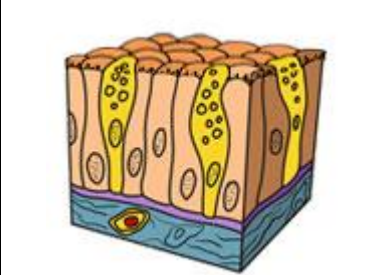
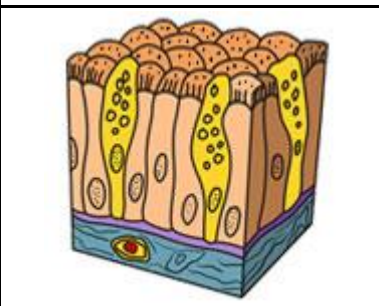
- These cells form a large percentage of household dust.

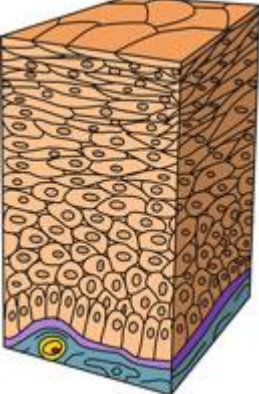
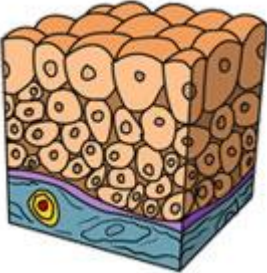
The Functions of Epithelial Tissue

Epithelial cells form the covering of all body surfaces, they cover the outside of the body and line all organs and cavities. In its simplest form it consists of a sheet of cells which fit closely together providing protection and preventing loss of fluid.

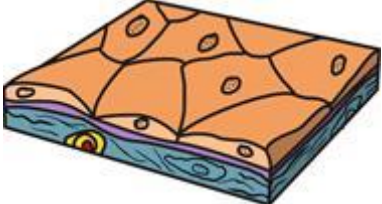

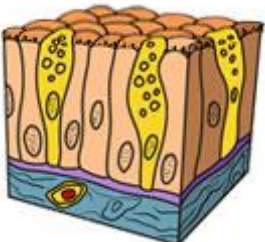
The Types of Epithelial Tissue

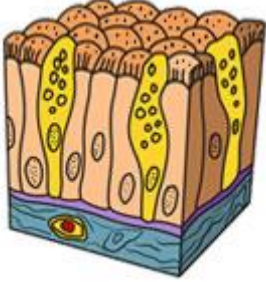
Epithelial cells are classified according to the number of cell layers and the shape of the cells.

IMAGE	NAME		DESCRIPTION
	Simple Squamous Epithelium.	Single Layer of cells.	Single layer of flat cells with a centrally located nucleus.
	Simple Cuboidal Epithelium.	Single layer of cells.	Single layer of cube shaped cells with a centrally located nucleus.
	Simple Columnar Epithelium.	Single layer of cells.	Single layer of rectangular shaped cells with the nucleus located at the base of the cell.
	Ciliated Simple Columnar Epithelium.	Single layer of cells.	Single layer of ciliated rectangular shaped cells with the nucleus located at the base of the cell.

	Stratified Epithelium.	Multiple layers of cells.	Consists of several layers of cells, with squamous cells in the surface or superficial layers and cuboidal and columnar in the deep layers
	Transitional Epithelium.	Multiple layers of cells.	Consists of multiple layers of cells whose appearance is variable or transitional

Simple Epithelium Tissue

IMAGE	SHAPE	LOCATION	FUNCTION
	Squamous. Single layer of flat cells with a centrally located nucleus.	They form the lining of cavities such as the mouth, blood vessels, heart and lungs and make up the outer layers of the skin.	They protect underlying tissue from mechanical injury and from excessive loss of water.
	Cuboidal. Single layer of cube – shaped cells with a centrally located nucleus.	Cuboidal epithelium is found in glands and in the lining of the kidney tubules as well as in the ducts of the glands.	In glands, epithelial tissue is specialised to secrete specific chemical substances such as enzymes, hormones and lubricating fluids.
	Columnar. Single layer of rectangular cells with the nucleus situated at the base of the cell.	Columnar epithelium forms the lining of the stomach and intestines.	In glands, epithelial tissue is specialised to secrete specific chemical substances such as enzymes, hormones and lubricating fluids.

	<p>Ciliated. Single layer of ciliated rectangular cells with the nucleus situated at the base of the cell.</p>	<p>Ciliated epithelium is usually found in the air passages like the nose. It is also found in the uterus and Fallopian tubes of females.</p>	<p>Ciliated epithelium assists in removing dust particles and foreign bodies which have entered the air passages. Also, the movement of the cilia propel the ovum to the uterus.</p>
---	---	---	--

NOTE: The epidermis is composed of stratified squamous epithelium

DERMIS

This layer lies directly below the epidermis and is formed by two distinct layers of different cells that form connective tissue. The cells of the uppermost layer of the dermis connect to the cells of the lowest layer of the epidermis. The second layer makes up the bulk of the dermis and contains the many structures associated with the skin including:

Key points.

- Lies under and connects with the epidermis.
- Continues the protective function of the skin.
- Formed from connective tissue
- Made up of two distinct layers
- The layer that connects to the epidermis is the papillary layer
- The underlying layer known as the reticular layer contains the structures associated with the skin e.g. Hair.

Papillary Layer

- Connects the dermis with the epidermis.
- Contains blood and lymphatic vessels that provide nutrients for the cells of the lower layers of the epidermis.
- A removal system for waste from these cells.

Reticular Layer

- Lies beneath the papillary layer
- Forms the bulk of the dermis.

- Contains protein fibres in the form of collagen, elastin and reticulin.
- Collagen provides the skin with strength, resilience and a youthful appearance.
- Elastin provides the skin with ability to stretch easily as well as regain its shape when necessary e.g. pregnancy.
- Reticulin provides support for all of the structures contained within the dermis, including:

Structures of the dermis.

Hair:

- Hair develops in the dermis in the hair follicles.
- Hair follicles have a rich blood, lymphatic and nerve supply.
- Extends up and out of the skin via a follicle opening or a pore.
- As the hairs extend out of the skin, the cells disconnect from the blood and nerve supply and start to die from a process of keratinisation.
- The hair shaft is the name given to the hair as it extends out of the skin.
- Lanugo hair is present on the body prior to birth and is usually shed shortly after.
- Vellus hair replaces Lanugo hair after birth, Vellus is fine and downy hair.
- Areas of the body requiring additional protection develop terminal hair which is thick and coarse.
- Hairs go through a growth cycle in which they grow, change and rest and eventually are shed.

Sebaceous gland:

- Small glands, which produce the skin's natural oil known as sebum.
- Attached to the hair follicles.
- Sebum travels up the hair follicles and exits onto the skin via a pore.
- Sebum lubricates the skin and the hair.

Arrector Pili Muscle:

- Connected to the epidermis and hair follicles.
- When these muscles contract, they pull the skin to form 'goose bumps.
- As they contract individual hairs are pulled upwards helping to trap warm air between the skin and hair.

Sweat glands:

- Technically classified as sudoriferous glands of which there are two types.
- Eccrine glands are found all over the body especially on the palms of the hands and the soles of the feet.
- Apocrine glands are found on the hairy parts of the body e.g. Underarms, groin and are larger than eccrine glands.
- Eccrine sweat glands are active from birth; they produce sweat with a high salt and water content that helps to regulate body temperature.
- Apocrine glands become active during puberty and they produce sweat that has a higher fat content than that produced by eccrine glands. Due to their location (warm moist areas) bacteria will feed on the fat content of the sweat, break down and so produce body odour.

Circulation:

- The dermis has a complex network of blood and lymphatic vessels.
- The blood vessels transport oxygen from the air we breathe into the body to the skin cells as well as nutrients from the food we eat.
- Oxygen and nutrients ensure cells are able to reproduce and repair in order to maintain good healthy skin.
- The blood vessels also transport waste products in the form of carbon dioxide away from the cells so that it can eventually be breathed out of the body.
- Lymphatic vessels pick up waste from the cells that the blood vessels are unable to take helping to free the cells from any unwanted or harmful substances.

Nerve supply:

- The dermis contains sensory nerves that connect the skin with the brain.
- These sensory nerves are able to detect changes in temperature, pressure and pain.
- The sensory nerves produce a message in the form of an electrical impulse that is sent along a network of nerves through the body to the brain.
- The brain interprets the message and sends formulates a response by sending a corresponding message to the muscles and organs of the body via the motor nerves.

Subcutaneous Layer

- Lies under the dermis.
- Is formed of connective tissue.
- Provides storage of fat from our diet.
- Also known as the hypodermis or subcutis.

- Made from two forms of connective tissue areolar and adipose.
- Areolar tissue forms a loose network of cells that provide strength, elasticity and support.
- Adipose tissue forms a network of fat cells that provide insulation and an energy source

Structural difference.

The characteristics of an individual's skin depend on their gender, ethnicity and skin type.

Gender:

- Differences in the structure of the skin of males and females occur during puberty when hormones dictate the various changes specific to each gender.
- The stratum corneum is generally 20% thicker in males.
- Adipose tissue accumulates more on the hips and thighs of women and the abdomen of males.
- Males have more collagen; collagen production tends to slow down in females during the menopause. This causes female skin to age faster than male skin.
- Hair growth is thicker on males, especially on the legs, arms, face and chest.
- The decrease and final cessation of head hair growth is more common in males than females.

Ethnicity:

- Differences in the structure of the skin occur in different ethnic groups as a result of genetic factors that have been inherited over thousands of years. Different ethnic groups may be classified as being Caucasian (white, Asian, black, Chinese and mixed).
- Caucasian skin types produce less melanin (colour pigment) than the other ethnic groups.
- Black skin types produce more melanin than other skin types.
- Black skins have more sebaceous and sweat glands than other skin types.
- Black skins have a thicker epidermis than other skin types.
- Hair growth differs from ethnic group to ethnic group.
- Caucasian skin types generally have light to medium amounts of facial/body hair.
- Black and Chinese skin types generally experience light facial and body hair.
- Mixed and Asian skin types may experience heavy facial / body hair.

Skin types: Differences in the characteristics of the skin occur as the skin types changes throughout life. Skin types and conditions may be categorised as being, oily, dry, dehydrated, sensitive, congested/blemished, combination, young and mature.

- Skin becomes thinner as it matures.

- Oily, blemished and congested skin types contain sebaceous glands that are overactive. Excessive amounts of sebum are produced. This is often associated with a young skin.
- Dry skin types contain sebaceous glands that are inactive and which do not produce adequate amounts of sebum.
- Dehydrated skin types experience dryness associated with lack of water in the body as a whole, making the skin feel dry and tight.
- Sensitive skin types tend to be finer in texture with the network of blood vessels appearing closer to the skin's surface.
- Combination skin types usually have oiliness down the centre of the face and dryness on the neck and cheeks.

Skin functions

As part of the integumentary system, the skin, hair and nails have many functions that contribute to the well-being of the body as a whole.

These specific functions include:

- **Sensitivity** – the skin is a sensory organ.
- **Heat regulation (temperature control)** – the skin helps to maintain a body temperature of 36.8°C.
- **Absorption** – the skin is able to absorb some water and moisture.
- **Protection** – the skin is able to protect the body like a living suit of armour.
- **Excretion** – the skin is able to eliminate waste through the elimination of sweat.
- **Secretion** – the skin is able to perform a cellular process of releasing a substance i.e. Sebum.
- **Production of vitamin D** – vitamin is produced in response to the action of sunlight on the skin.

Sensitivity

The skin picks up sensation from our environment:

- The sensations of touch, pressure, pain and temperature are transmitted to the brain via an elaborate network of sensory nerves and receptors in the skin.
- These sensations are transmitted as electrical impulses.
- The brain receives and interprets the messages.
- The brain formulates a response that it relays as electrical impulses back to the body along a corresponding set of nerves called motor nerves.



- Some messages bypass the brain these are known as reflex actions which allow the body to respond quickly e.g. Move away from a hotplate etc.

Heat Regulation

The skin helps to maintain body temperature through sweating, vasodilation, vasodilation, fat cells in the subcutaneous layer and production of 'goose bumps.

- As body temperature rises, the sudiferous glands produce sweat. The heat of the skin evaporates the sweat producing a cooling effect on the skin.
- When the body temperature rises, blood vessels dilate to allow blood to flow closer to the skin and therefore reduce heat. This action is **vasodilation**.
- When body temperature falls, blood vessels constrict, causing the blood to flow slower and further away from the skin's surface, therefore conserving heat; this action is called **vasoconstriction**.
- Fat cells in the subcutaneous layer help to insulate the body against excessive heat loss.
- When we are cold, we have an involuntary action of shivering. This action causes the arrector pili muscles attached to the hair follicles in the dermis, to contract, pulling at the hair follicles and causing goose bumps on the skin's surface where the tiny hairs are lifted in an attempt to trap warm air beneath them.

Absorption

Absorption of water / moisture is controlled by the acid mantle and the stratum lucidum in the epidermis.

- The acid mantle forms a protective covering to the skin that is able to absorb limited amounts of moisture in the form of creams and oils etc.
- The stratum lucidum prevents excessive amounts of water and moisture from entering the body.
- Certain substances with a particular molecular structure are able to penetrate more deeply through a process called diffusion.
- Examples of substances that are able to be absorbed by the process of diffusion are essential oils.

Protection

The skin protects the body through the formation of the acid mantle, the production of melanin, fat cells in the subcutaneous layer, touch, blood clotting and with the hair and nails.

- Protective covering called the acid mantle is formed by the combination of sweat and sebum with the surface dead skin cells of the epidermis.
- The acid mantle has an acidic ph. of between 4.6 and 6 helping to protect the skin's surface.

- The production of melanin (colour pigment) in epidermis occurs when the skin is exposed to sunlight.
- Melanin production forms the characteristic suntan offering the body a form of protection from burning and harmful effects on the underlying tissues.
- Fat cells in the adipose tissue of the subcutaneous layer form a protective 'cushion' for the body.
- 'Touch' alerts the brain to impending danger helping to protect against damage from extreme temperature, pressure and pain.
- Blood cells help protect the skin when damaged by producing a clot or scab over a wound.
- Hair develops from follicles in the dermis, offering additional protection to more delicate areas of the body.
- Nails develop from the cells of the stratum germinativum in the epidermis and protrude out of the skin to protect the ends of the fingers and toes.

Excretion

- This is eliminating waste.
- Sweat is produced by the sweat glands.
- Sweat contains water together with small amounts of waste products including urea, uric acid, ammonia and lactic acid.

Secretion

This is a cellular process whereby a substance is released.

- Sebum is produced by the sebaceous glands in the dermis.
- Sweat is produced by the sweat glands in the dermis.
- Sebum and sweat are released onto the surface of the skin via pores.
- Sebum and sweat combine with dead skin cells to form the acid mantle.

Production of Vitamin D

- Vitamin D is produced by the skin in the presence of sunlight.
- The skin contains a fatty substance called ergosterol.
- Ergosterol is converted into Vitamin D in response to stimulation from the ultraviolet rays of the sun.
- Vitamin D helps the body store calcium, which is needed for healthy bones.

The skin – fascinating facts.

- One square centimetre of skin contains approximately 15 sebaceous glands, 100 sweat glands, 3 metres of nerves and 1 metre of blood vessels!
- The skin plays hosts to lots of 'good' bacteria that live on its surface helping to protect the body.
- We shed approximately 4% of our total skin cells every day.
- An average adult has approximately 100,000 head hairs.
- The tips of the fingers and toes absorb more water than any other part of the body.
- Skin makes up approximately 12% of an adult's total body weight.
- Skin relies on a balanced diet to keep it fit and healthy.
- Pollution can be absorbed through the skin e.g. Cigarette smoke.

Types of hair growth:

Hair forms part of the integumentary system along with the skin and nails. They are formed from a protein called Keratin and develop from hair follicles within the dermis. Hair is present all over the body except on the lips, palms of the hands, soles of the feet and parts of the genital area.

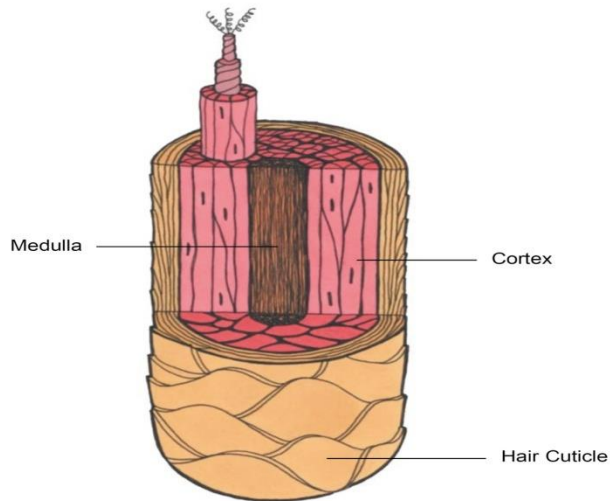
Different types of hair:

- **Lanugo hair** – present on the body prior to birth; it grows from around the third to fifth month of pregnancy and is usually shed prior to birth. Soft and downy, these hairs do not have a medulla and very often lack pigment.
- **Vellus hair** – these hairs usually develop by the seventh to eight months of pregnancy, replacing lanugo hair. They are shallow rooted, fine, soft and downy and found on the face and body. Vellus hairs often lack pigment and a medulla; if their shallow follicles are stimulated, the roots can grow downwards and develop stronger, terminal hairs.
- **Terminal hair** – deep rooted, coarse and pigmented hairs found covering areas of the body requiring additional protection. Terminal hair is the coarse hair of the scalp, inside the ears, the eyebrows, eyelashes, underarm and pubic regions protecting the vulnerable areas which lie below i.e. the brain, the eyes, and the glands under the arms and the genitals. It is also present on the faces and chests of men.

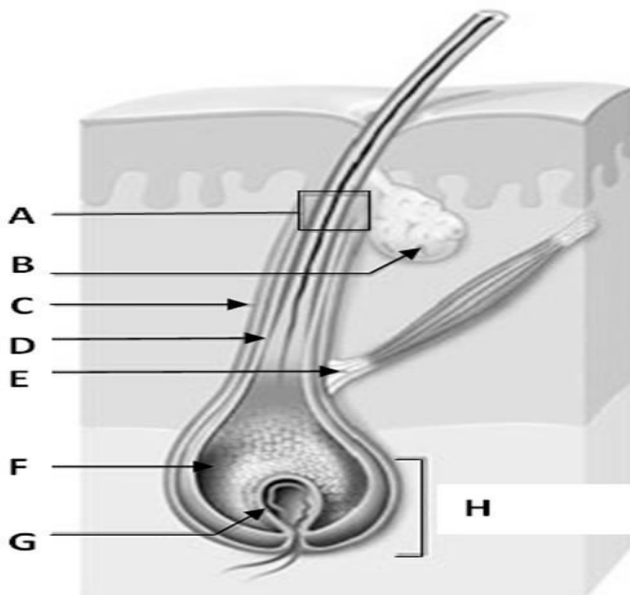
PLEASE NOTE: the main function of the hair is to keep the body warm and to insulate and protect.

Slide **A&P 6.1a**

Layer of the hair

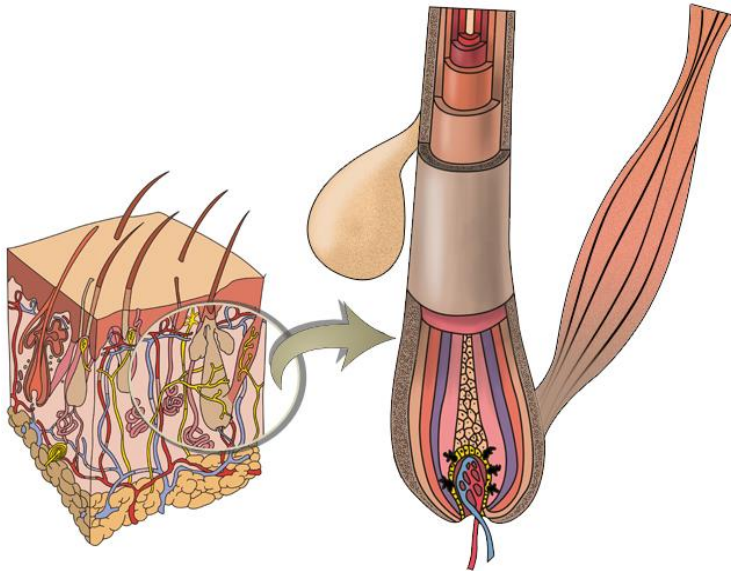


© Copyright Habis 2010 - All rights reserved.



A	Hair shaft
B	Sebaceous gland
C	Outer root sheath
D	Inner root sheath
E	Arrector pili muscle
F	Hair matrix
G	Dermal papilla

H	Hair bulb
----------	------------------



C	Medulla	A	Arrector pilli muscle
F	Cortex	B	Matrix
D	Cuticle	G	Dermal papilla
E	Sebaceous gland	H	Blood vessel

Layers of the hair – the structure of the hair

Hairs are made up of three distinct layers:

- **Medulla** – innermost layer made up of loose cells. Not always present in all hairs or even within the length of the same hair thus giving a difference in texture and sheen.
- **Cortex** – middle layer of the hair containing keratinocytes (cells responsible for the protein keratin) and melanocytes (cells responsible for producing the colour pigment melanin present in the hair).
- **Cuticle** – outermost layer made up of flat, overlapping cells. Inside the skin, these cells interlink with those of the hair follicle, helping to anchor the hair. Outside the body, these cells provide a protective coating to the hair.

Structures associated with hair growth:

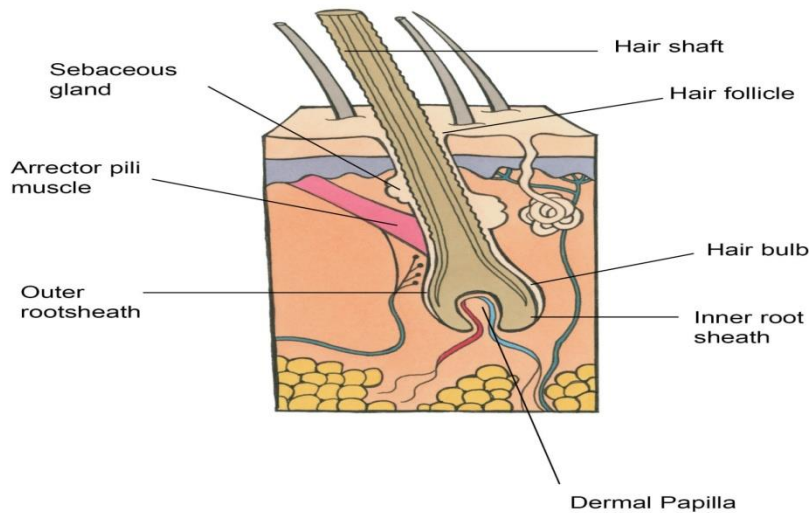
- **Hair follicle** – a sac-like structure which extends from an opening or pore on the surface of the skin down into the layers of the epidermis, dermis and in some cases the subcutaneous layer.

- **Hair bulb** – the base of the hair follicle containing the matrix or hair root. The cells within the matrix reproduce new cells by simple cell division known as mitosis, pushing old cells upwards in much the same way as the cells in the layers of the epidermis.
- **Dermal papilla** – provides a connection with the papillary layer of the dermis to offer the hair producing cells of the matrix a supply of blood and nerves.
- **Root sheath** – surrounding the hair cells and made up of an inner portion and outer portion. The inner root sheath contains three layers the cuticle layer, Huxley's layer, and Henley's layer and helps to secure the hair within the follicle. The inner root sheath stops growing when it becomes level with the sebaceous gland. The outer root sheath is continuous with the stratum germinativum of the epidermis and forms the follicle wall. It allows the renewal and development of hair cells to take place.
- **Hair shaft** – a strand of hair which can be seen on the surface of the skin as it emerges from the follicle. As the hair cells are pushed up through the bulb, they become keratinised and develop into hard layers of dead cells resulting in the hair shaft.
- **Sebaceous glands** – attached to hair follicles producing the natural oil sebum.
- **Arrector pili muscles** – tiny muscles that attach to the hair follicle and the epidermis. When these muscles contract, they make the hair stand erect pulling the skin into 'goose bumps' in an attempt to trap warm air against the skin.

NOTE:

The term pilosebaceous unit refers to a structure that is made up of hair in its follicle, the arrector pili muscle and the sebaceous gland.

Structure associated with hair growth



© Copyright Habia 2010 - All rights reserved.

Hair Growth:

Individual hairs can grow up to 12mm a month, but they do not grow continuously. They have a growth cycle, which takes them through three distinct phases:

1. **Anagen – growing phase**
2. **Catagen – a changing phase**
3. **Telogen – a resting phase**

Hair growth: Anagen the active phase of the hair cycle.

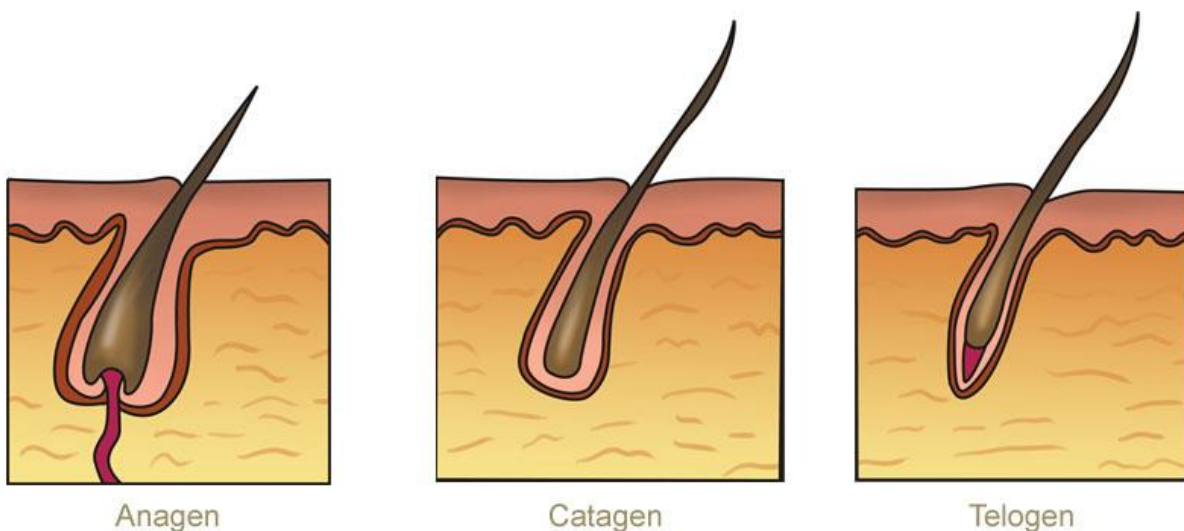
Anagen is the first phase of the hair growth cycle and is initiated by the endocrine system, releasing a hormone into the blood stream, sending it to the outer root sheath. The outer root sheath is then stimulated into activity and a **dermal cord** is produced linking the hair follicle at the dermal papilla. A new hair develops from cells in the matrix section of the hair bulb at the base of the follicle and the dermal cord provides the means for the hair cells to receive nourishment from the dermal papilla to allow simple cell division (mitosis) to take place. The dermal papilla also provides the hair cells with a nerve supply making it painful for hairs in this stage of growth when they are forcibly pulled.

Catagen is the second phase of the hair growth cycle. It involves the hair cells passing up through the follicle, carried by the movement of the inner root sheath, up to the base of the sebaceous gland. As the hair is now fully grown and as it does not need the matrix anymore, it detaches from it. This phase can be very short, with a new hair growing straight away; or slower, with the hair staying where it is until it falls out, with the papilla and the follicle below the level of the sebaceous gland degenerating and entering a resting phase called telogen.

Telogen is the third and final phase of hair growth cycle. The hair dries up and eventually falls out leaving room for the whole cycle to begin again. Many hair follicles do not go through this phase; they start to grow a new hair immediately. This varies from person to person and is also dependent on hormonal changes.

The phase of hair growth follows a continuous pattern involving the following:

1. **Action** – anagen phase which can last for up to six years.
2. **Change** – catagen phase which takes place over a few days.
3. **Termination** – telogen phase which lasts for varying lengths of time and is dependent on hormone release to activate the new growth associated with anagen. Sometimes a new hair develops before the old hair has been released.
4. Individual hair follicles pass through these phases at different times; therefore, some old hairs are always falling out. The majority of hairs will be at anagen phase with the least amount of hairs being at the telogen phase at any one time.



A-Z Hair facts.

African-Caribbean hair type is tightly curled, as the hair follicles are oval, which makes the hair grow in a spiral-like fashion; with light facial/body hair growth.

Hormones – hormone imbalance and crash dieting can trigger temporary hair loss.

Canities – grey or white hair due to lack of colour pigment (melanin) forming in new hairs; associated with ageing.

Caucasian European hair is generally straight or loosely waved, with medium amount of body hair.

Club hairs – hairs in catagen phase of growth usually have a clubbed end as the hair bulb disengages.

Corkscrew hair – distortion of the hair follicle resulting in tightly curled hair.

Dehydrated hair – lacking in moisture because of the use of harsh products and/or exposure to extreme temperatures.

Dry hair – hair that is lacking in moisture because of underactive sebaceous glands.

Eastern hair type is coarse and straight, as the hair follicles are almost completely round, making the hair straight; with light facial/body hair.

Embedded hair – hair that does not exit the skin as it should, creating a small bump on the surface.

Hirsutism – abnormal hair pattern of hair growth involving a male pattern of hair growth in females.

Hypertrichosis – abnormal growth of hair involving hair growth in unusual areas of the body.

In growing hairs – hairs which continue to grow below the surface of the skin. Prone to becoming infected unless loosened from the skin to grow normally.

Latin hair type is coarse, straight and dark with heavy facial/body hair.

Monilethrix – irregular development of hair in the follicle, resulting in bead-like swellings along the hair shaft.

Oily hair – an over secretion of sebum coating the hair shaft.

Pili multigemini – two or more hairs growing from the same follicle.

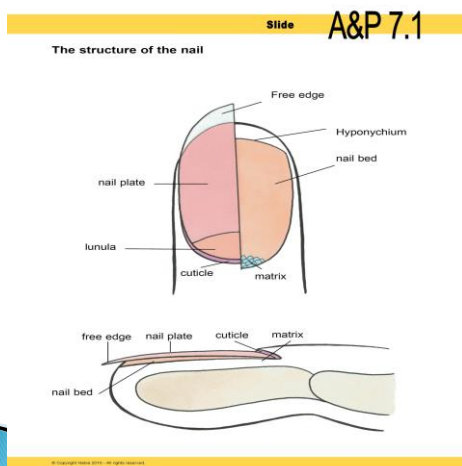
Superfluous hair – unwanted hair as a result of heredity, hormonal changes or stimulation of the area.

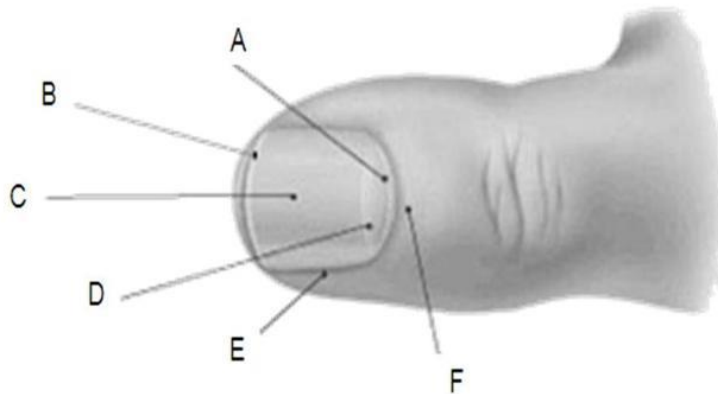
The structure of the nail:

Nails develop from the cells of the **stratum germinativum** in the epidermis as hard structures that protrude to cover the tips of the fingers and toes. The structure of the nail includes:

- **Germinal matrix** – the root of the nail, situated in the stratum germinativum; it forms the cells which will eventually produce a nail. These cells subdivide by a process of simple cell division (**mitosis**) pushing old cells upwards and gradually start to harden through the process of keratinisation. This portion of the nail does not have any melanocytes. The edge of the germinal matrix is seen as a white, crescent shaped structure called the **lunula**.
- **Lunula** – identified through its half-moon shape, is located at the base of the nail. This is where the cells of the matrix are still undergoing keratinisation, so it can feel soft and spongy in comparison to the hardened cells further up in the nail plate.

- **Nail Plate** – consists of compact layers of clear cells which have developed with the layers of the epidermis and form an extension of the skin at the ends of the fingers and toes. The cells are now **dead**, filled with **keratin** and are held together in longitudinal layers with fat, but very little moisture. The underside of the nail plate is grooved with longitudinal ridges, which allow it to interlock with the underlying nail bed; helping to keep it in place. **The nail plate consists of a translucent layer of keratinised epidermal cells with fat and moisture. They grow 3mm a month.**
- **Nail bed** – lies directly below the nail plate and is responsible for securing the nails to the finger or toe. The cells of the surface of the nail bed interlock with the cells of the underside of the nail plate forming a secure bond. The nail bed has a very good blood supply providing the cells with the nourishment required for healthy growth; this is evident through the '**pink**' appearance of the nail plate, as you can see the blood supply through the translucent cells of the nail plate.
- **Free Edge** – the end of the nail plate that extends over the nail bed.
- **Nail Cuticle** – develops as an extension of the **stratum corneum** of the epidermis creating the nail fold. It starts as the **eponychium** at the lunula, attaching itself to the nail plate protecting the underlying germinal matrix against damage and invasion. It surrounds the nail plate as the **perionychium**, extending under the top of the nail plate as the **hyponychium**, offering protection to the nail bed and preventing particles from getting under the nail plate.
- **Nail Grooves** – guide the nail plate up the fingers and toes at the sides, helping to keep it on 'track'. Grow straight
- **Lateral Nail Wall** – folds of the skin overlapping the sides of the nail plate, protecting the nail grooves and nail plate edges
- **Nail Mantle** – the skin lying directly above the germinal matrix, before the start of the cuticle. It appears as a deep fold of skin.
- **PLEASE NOTE: The main function of nails is to protect the ends of the fingers and toes from physical trauma**





A	Eponychium
B	Free edge
D	Lunula
F	Nail matrix
C	Nail plate
E	Nail wall

Factors affecting nail growth, development and condition.

Nails grow continuously throughout life, starting from the third month of foetal development.	If the blood circulation to the nail is good, the nail bed will appear pink and this will show through the transparent layers of the nail plate.
It takes approximately six months for fingernails to grow from the matrix to the free edge.	If the blood circulation is poor, the nail bed will appear white or even blue and this will show through the transparent layers of the nail plate.
Toenails take twice as long to grow than fingernails.	Illness affects the growth rate, development and condition of the nail plate.
Nails grow faster in the summer than in the winter.	Doctors often check the colour and condition of our nails as this gives them an insight into the overall health of the body.

Nail growth slows down with age.	Damage caused to the germinal matrix will cause permanent damage to the growth and development of the nail plate.
Toenails are thicker than fingernails.	Damage to the germinal matrix may result in the complete absence of nail growth in the extreme or the development of permanent ridges and/or discolouration of the nail plate.
Nails often become thicker with age.	Harsh products and extreme temperatures affect the moisture and fat content of the nail plate encouraging peeling of the layers.

Healthy nail growth is dependent on a good blood supply to the germinal matrix.

Nail condition	Medical referral required		
	NO	YES	
Leuconychia (white spots)	X		
Overgrown cuticles	X		
Warts		X	
Scabies		X	
Bruised nail	X		
Ringworm		X	
Hangnail	X		
Cuts & abrasions	X		
Bitten nails	X		
Healed psoriasis	X		
Dry/flaking nails	X		
Weeping eczema		X	
Onychosis		X	
Furrows	X		

Treatable nail disorders

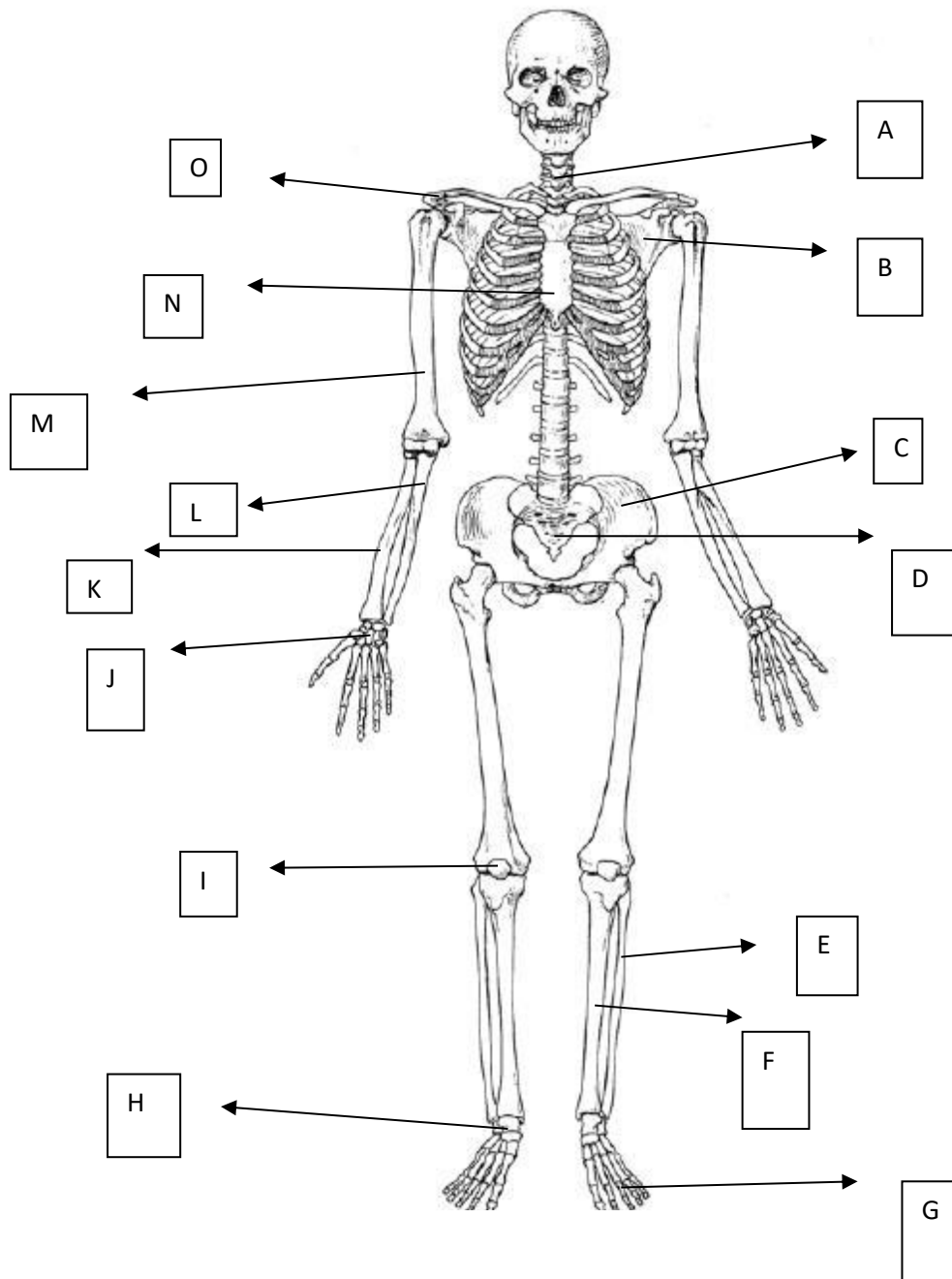
Correct name	Cause & appearance	Treatment
Leuconychia	White spots, which appear on the nail frequently, caused by injury, lack of zinc, calcium or maybe air spaces between the tissue cells.	These will eventually grow out of the nail plate. Avoid applying pressure on the cuticles during the nail treatment.
Corrugations	Vertical or horizontal ridges within the nail plate. Vertical ridging can be caused by damage to the matrix. Horizontal ridging on all the nails can be caused by an illness.	If the ridges are not too severe use a buffer and buffing paste to remove them. Horizontal ridges will eventually grow out. Avoid using coloured polish as this will emphasise the condition.

Hangnails	Loose, flaky pieces of dry skin which can be caused by picking the cuticle and surrounding skin or when too removing much cuticle during the nail treatment.	Remove with cuticle nippers and recommend cuticle massage cream or oil treatments to prevent dryness from occurring.
Pterygium	Forward growth of the cuticle from the base of the nail, which sticks to the nail plate.	Careful use of the cuticle knife and nippers to remove excess. Regular nail and oil treatments to prevent re growth and keep cuticles soft and supple.
Onychophagy	Bitten nails often caused by a nervous induced habit. The hyponychium is often left exposed and the cuticle and surrounding skin is ragged. Nail biting can result in the nail plate growing deformed and infection can occur.	Regular treatments to help encourage growth and overcome the habit.
Onychorrhaxis Split nail	Vertical or horizontal splits in the free edge of the nail can be caused by careless filing, excessive use of detergents, polish removers etc.	Only use the fine side of the emery board when filing. Advise regular oil treatments and nail strengthening treatments.
Blue nails	The nail plate appears blue in colour instead of pink. Can be a hereditary disorder, or poor	Increase the circulation by buffing and massaging the area regularly. Advise regular skin and nail

	circulation due to the cold or a heart disorder.	treatments to stimulate the circulation.
Brittle nails	The nails tend to be thick and yellow in colour and break easily. In some instances, it can indicate an iron deficiency or anaemia.	Apply cuticle massage cream/oil regularly especially at night. Apply nail strengthening treatments. Recommend protective gloves when cleaning etc.
Flaky nails	This is caused by dryness due to exposure to chemicals and solvents. The layers of the nail plate separate at the free edge.	Only file the nails with the fine side of the nail file. Regular use of cuticle cream/oil and nail strengtheners. Always use a polish remover that contains oil. Recommend protective gloves when cleaning etc.
Beaus lines	This can be caused by dermatitis, illness, shock or vigorous massage. The nails tend to be ridged and furrowed.	The nails tend to be fragile therefore care must be taken when carrying out the manicure treatment.

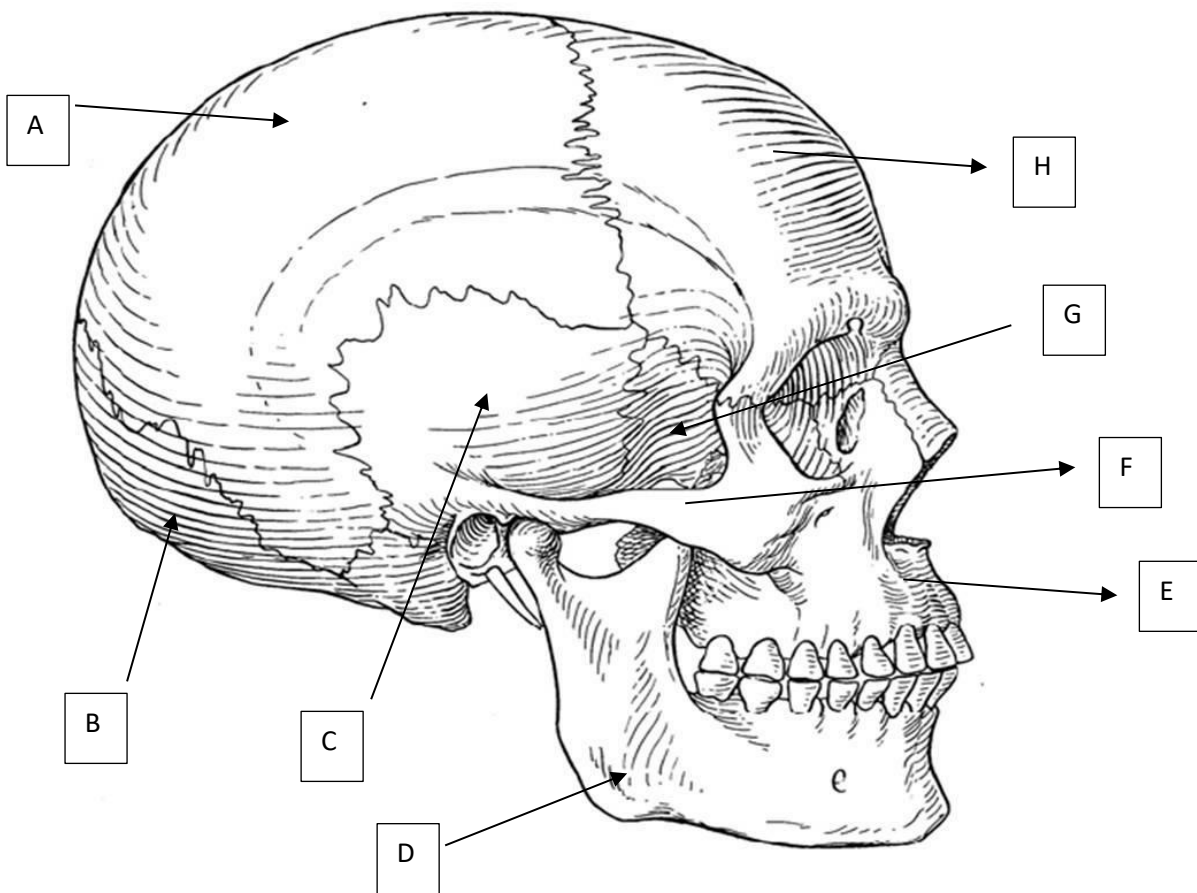
SKELETAL SYSTEM

BONES OF THE SKELETON REVISION TEST



G	Phalanges
C	Ilium / pelvic girdle
K	Radius
J	Carpals
L	Ulna
D	Sacrum
F	Tibia
O	Clavicle
I	Patella

N	Sternum
E	Fibula
H	Tarsals
B	Scapula
M	Humerus
A	Cervical Vertebrae



H	Frontal
B	Occipital
A	Parietal
C	Temporal
G	Sphenoid
D	Mandible
F	Zygomatic
E	Maxilla

Bones of the cranium

1 Frontal bone forming the forehead.

It contains two sinuses, one above each eye.

2 parietal bones forming the crown of the head.

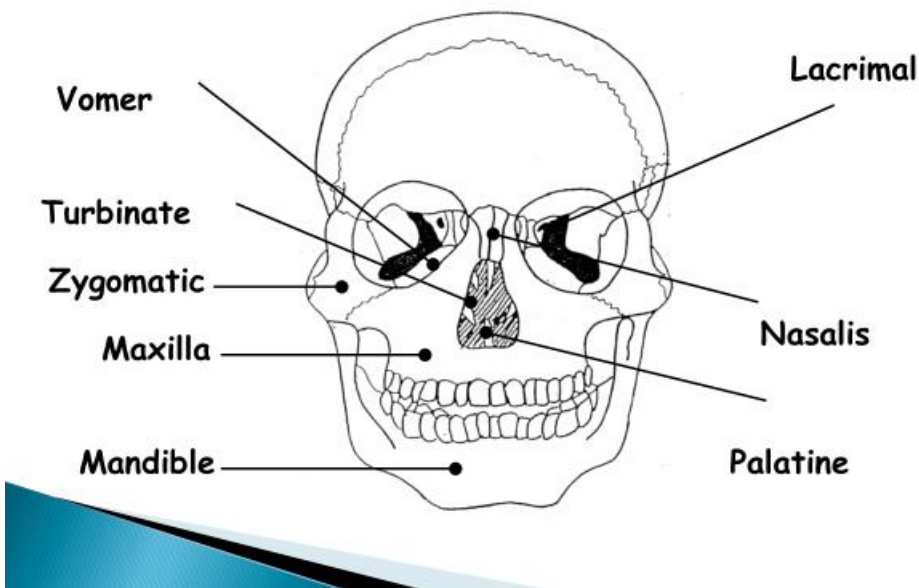
1 occipital bone forming the base of the head.

2 temporal bones forming the temples at the side of the head.

1 ethmoid bone forming part of the nasal cavity. It contains many small sinuses. **The ethmoid bone forms part of the eye orbits and the roof of the nasal cavity.**

1 sphenoid bone forms the base of the cranium at the back of the eye socket. It contains two sinuses that drain mucus into the very back part of the nose.

Bones of the face



2 **zygomatic** bones forming the cheeks

2 **maxilla** bones fuse together forming the upper jaw containing the sockets for the upper teeth and the largest pair of sinuses.

1 **mandible** bone forming the lower jaw containing the sockets for the lower teeth.

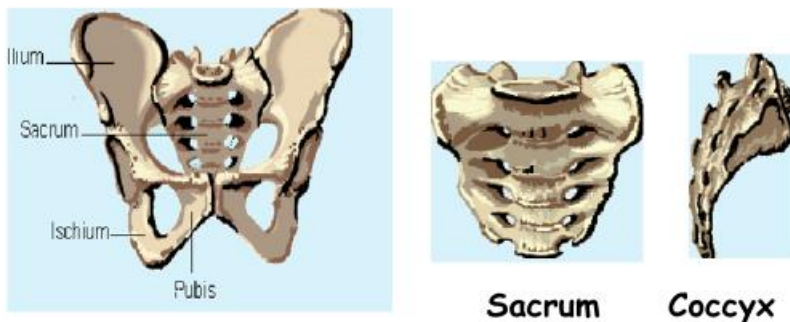
2 **nasal** bones forming the bridge of the nose.

- 2 **palatine** bones forming the floor and the wall of the nose and roof of the mouth.
- 2 **turbinate** bones forming the sides of the nose.
- 1 **vomer** bone forming the top of the nose.
- 2 **lacrimal** bones forming the eye sockets and contain an opening for the tear duct.

HIP GIRDLE

2 x Pelvic bones

(each consisting of Ilium, Ischium, and Pubis)



19

Main Functions of the Skeleton System

The skeleton is a bony framework which supports the body and keeps us in an upright posture.

The skeleton provides protection for internal organs, e.g. the skull protects the brain. The **vertebrae** protect the spinal cord; the pelvis protects the reproductive organs and the bladder.

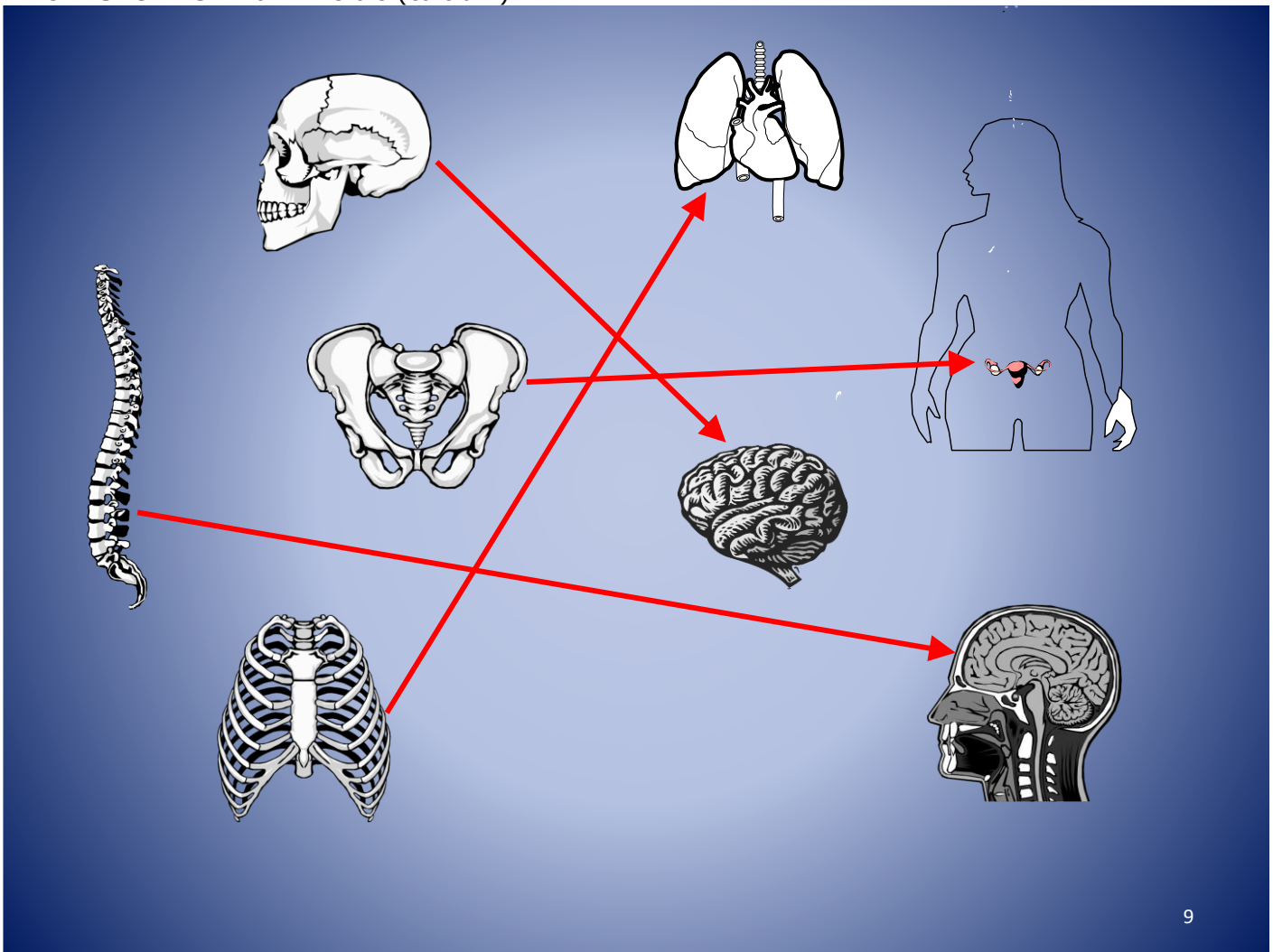
The rib cage protects the heart and lungs assists with inspiration and expiration. Bones provide surfaces for the attachment of muscles which together, produce movement. Inside the bones, red and white blood cells are made and minerals such as calcium and phosphate are stored.

RECAP

The main functions of the skeleton are;

1. **SUPPORT**- in an upright posture
2. **PROTECTION** - of internal organs
3. **MOVEMENT** - with aid of muscles
4. **BLOOD CELLS** - are made inside the bones

5. STORAGE - of minerals (calcium)



BONES

Bones are not dead material – 1/3 of them are living tissue with a constant turnover of cells carrying out the jobs of maintenance and repair. Bones are serviced by blood vessels, nerves and lymph vessels which run through a labyrinth of tiny canals. **Special** cells called Osteoblasts dissolve and break down damage bones so they can be repaired.

COMPOSITION OF BONE

The skeleton is composed of two types of tissue:

1. **Cartilage**
2. **Bone**
3. **Bones are primarily composed of calcium and phosphorus,**

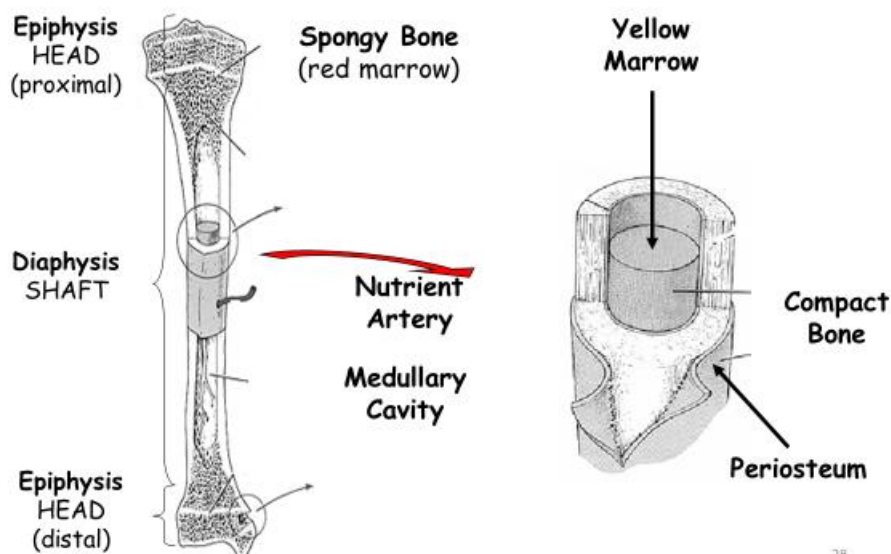
CARTILAGE

- Provides the environment in which bones develops.
- Has a clear matrix of gelatinous protein.
- Softer than bone, less rigid, slightly elastic.
- Strengthened by collagen and elastin fibres.
- The foetal skeleton is temporarily formed of cartilage.
- It is gradually replaced by bone by the process of ossification except for limited areas such as the ear and nose.

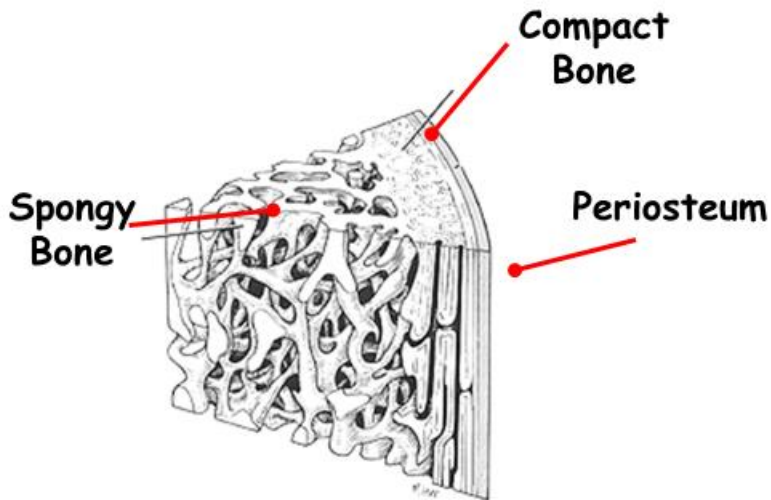
BONE

- A Rigid, dense, non-elastic tissue.
- Bone forms during growth as minerals, bit by bit, replace cartilage.
- Two types of bone; **Compact** (hard) and **Spongy**.
- In a long bone compact bone forms the outside and a light, honeycomb of cancellous tissue is in each bulbous end –which also holds red marrow. There is yellow marrow in the medullary cavity.
- **Short bones are cube shaped, mainly spongy bone with a thin surface of compact bone**

STRUCTURE OF A BONE

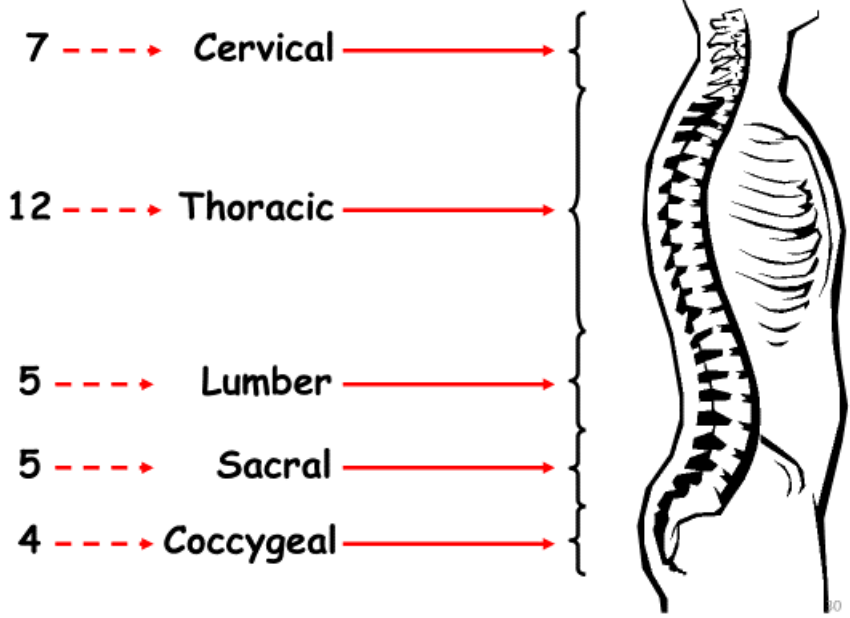


28

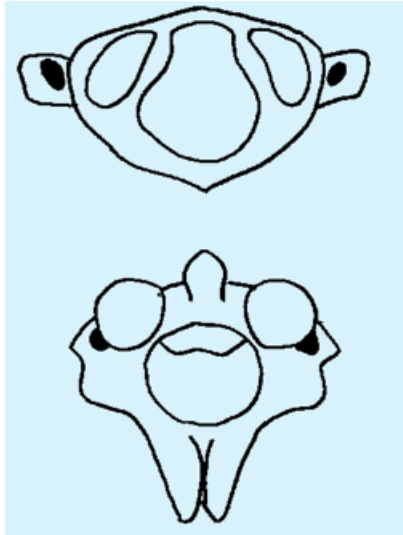


29

Regions of the Spine



THE SPINE



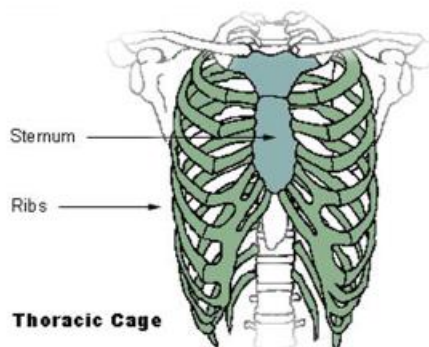
The Atlas

The Axis

14

Top two bones of the spine

Bones of the chest

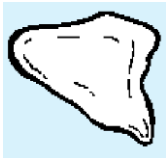

- 12 pairs of ribs that extend around from the spine.
- Sternum or breastbone to which some of the ribs attach at the front of the body.
- The ribcage protects the heart, lungs and assists with inspiration and expiration.

Types of Bones

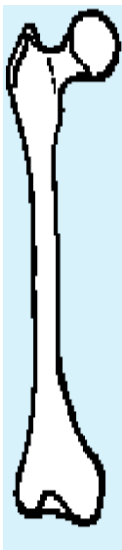
Bones are grouped and recognised according to their shape:

FLAT



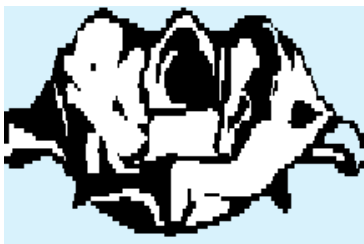E.g. scapula

LONG



E.g. Femur

IRREGULAR



E.g. Vertebrae

SESAMOID

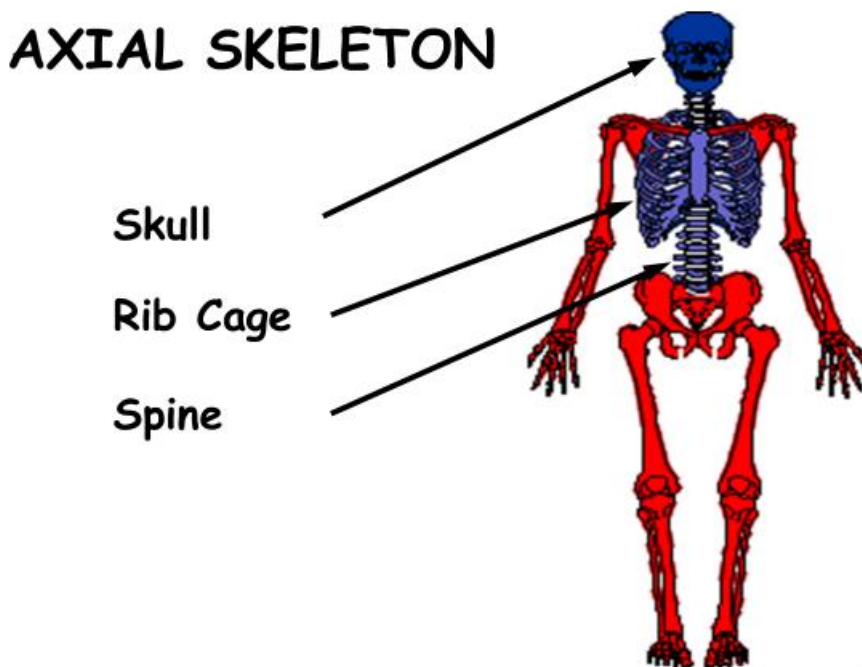


E.g. patella

BONE GROWTH AND REPAIR

Plentiful supplies of calcium and phosphorus are essential in the diet of pregnant women and nursing mothers, growing children and where bone repair is taking place after injury or disease. Milk, eggs and

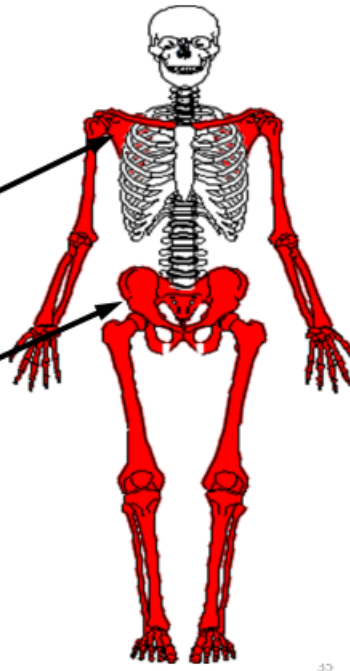
green vegetables are a good source of calcium and meat, fish and the yolks of eggs for phosphorus. Vitamin D is important for calcium and phosphorus to be absorbed from the intestine and fully utilised by body; Lack of this vitamin can cause brittle bones. Vitamin D is found in animal fat and fish oils and is also produced in the skin by the UV rays from the sun. Healthy bone growth is also dependant on vitamin C, which contributes to the laying down of collagen - the main constituent of connective tissue. Found in fresh fruit, particularly citrus fruit, blackcurrants, green vegetables, tomatoes and potatoes. Exercise and rest can affect the growth and development of bone. Exercise increases the blood supply to the muscles therefore to the underlying bone - the blood, rich in necessary building materials, causes an increase in growth to the bones. The effect rest has on growing bones is also recognised. The bones of a child are reasonably elastic so that at the end of a day of standing and running about there is an appreciable loss of height – during rest the bones recover their full length.



APPENDICULAR SKELETON

Shoulder girdle
and upper limbs

Pelvic girdle
and lower limbs



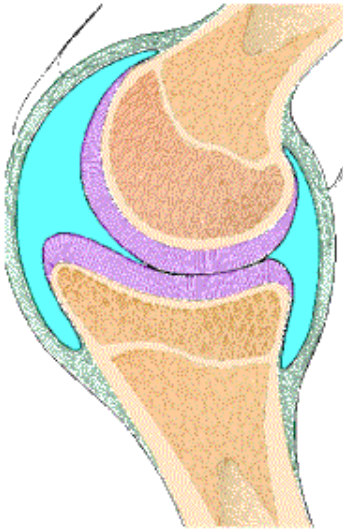
Bones & Joints

Bones are connected to each other by connective tissue and where two bones meet a joint is formed. Without joints the skeleton would not be able to move or have very limited movement. Fibrous connective tissue is used for immovable joints such as the cranium, whereas fibro-cartilage is used for semi-moveable joints such as the vertebrae. However, the most common joints are synovial joints and these hold freely moveable joints together by a connective tissue called a ligament.

STRUCTURAL CLASSIFICATION

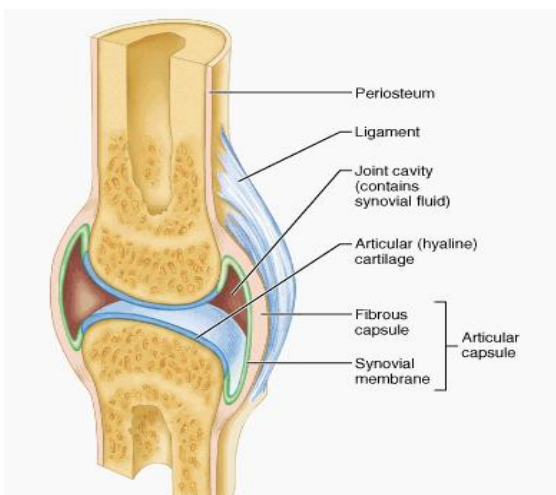
- **Fibrous** (immovable or slightly movable) no synovial cavity held together by fibrous tissue
- **Cartilaginous** (immovable or slightly movable) no synovial cavity held together by cartilage
- **Synovial** (all freely movable) a synovial cavity filled with synovial fluid surrounded by a capsule

Synovial joints



Synovial joints have a fibrous capsule that is lined with the synovial membrane which secretes the synovial fluid to lubricate the joint. Articular cartilage coats the ends of the bones to protect against wear and tear by reducing friction at the joint. Extra ligaments may surround the outside of the joint to provide extra strength and some also contain discs of cartilage to maintain stability. However, the main support to the joints is provided by muscles.

- Most common type of joint
- They allow varying amounts of free movement between the bones
- Amount of movement is determined by the type of synovial joint.
- There are 6 different types



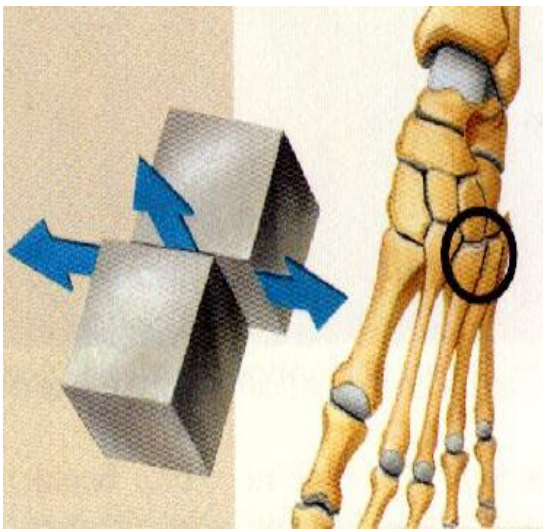
- All synovial joints have a similar basic structure consisting of:
- Ligaments
- Articular cartilage
- Articular capsule
- Synovial fluid

TYPES OF SYNOVIAL JOINTS

- . Gliding

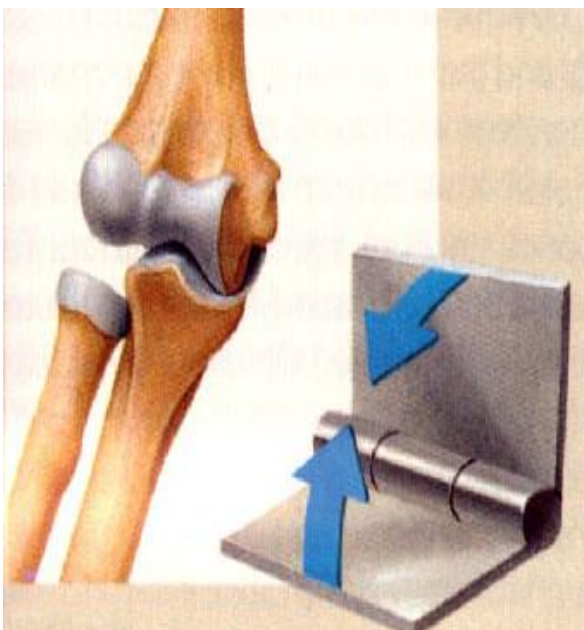
- 2. Hinge
- 3. Pivot
- 4. Condyloid
- 5. Saddle
- 6. Ball and socket

GLIDING JOINT



- Two flat surfaces slide against one another
- Allows only limited side to side, back and forward movements
- Carpal to carpal

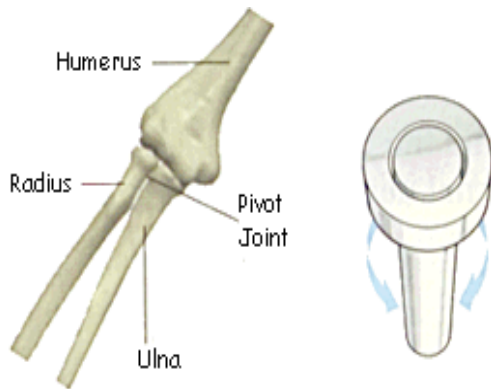
HINGE JOINT



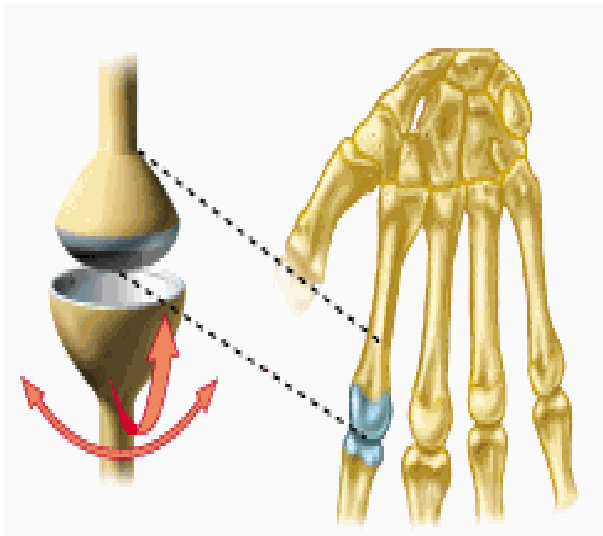
- Allows only flexion and extension
- humerus to ulna
- phalange to phalange
- femur to tibia
- lower leg to talus

PIVOT JOINT

- Allows rotation only
- atlas to axis
- radius to ulna

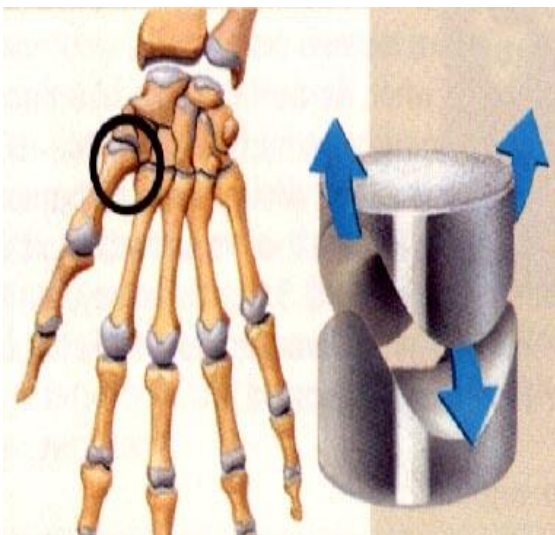


CONDYLOID JOINT



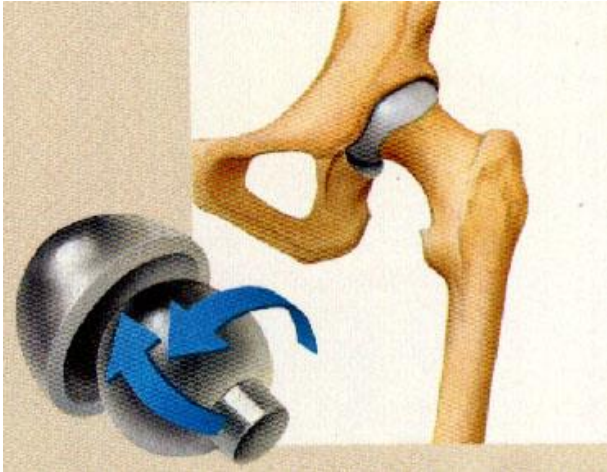- Allows flexion, extension, abduction, adduction and limited circumduction
- forearm to carpals
- occipital to atlas
- Metacarpal to phalanges

SADDLE JOINT



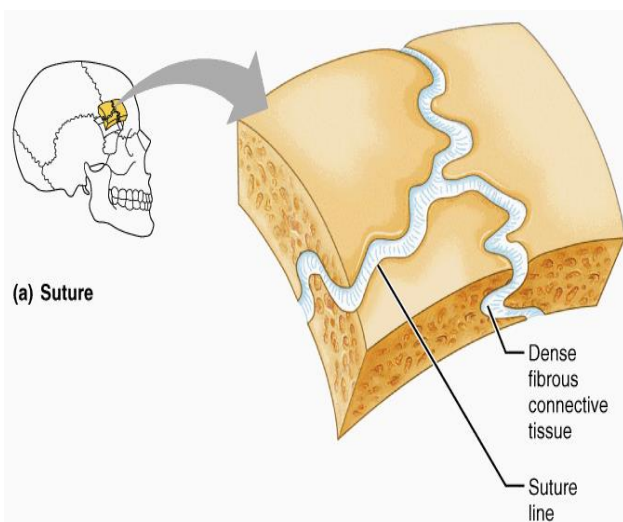
- Only found at base of thumb joint Allows flexion, extension, abduction and adduction
- metacarpal and trapezium

BALL AND SOCKET JOINT



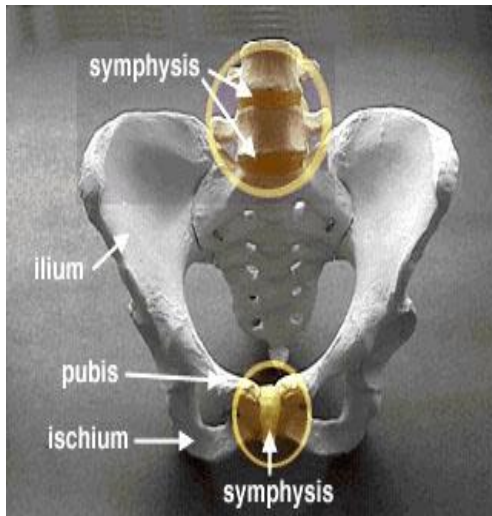
- Allows flexion, extension, abduction, adduction and circumduction
- Scapula to Humerus
- Hip to Femur

FIBROUS JOINTS



- **Suture**
- Sutures occur in the skull where adjacent bones articulate at their edges. A thin layer of fibrous connective tissue separates the bones.

CARTILAGINOUS JOINTS



- **Symphysis**
- A symphysis is where the opposite bony surfaces are covered by hyaline cartilage but connected by a fibrocartilage disc
- The spine.

LIGAMENTS

- Strong bands of collagen fibres which hold the bones together and limit/control the movement of the joint

ARTICULAR CARTILAGE

- Protects the ends of the bones.
- Reduces friction between the bones

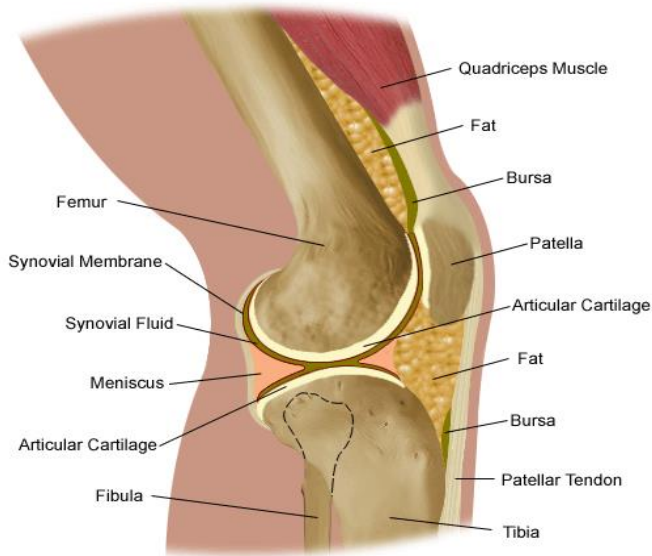
ARTICULAR CAPSULE

- A strong fibrous tissue envelope surrounding the joint
- This is reinforced by ligaments

SYNOVIAL MEMBRANE

- Lines the inside of the articular capsule (not covering articular cartilage)
- It produces synovial fluid

Anatomy of the Knee



Please note: The arches of the foot provide support to the foot and absorbs shock!!

The Muscular System

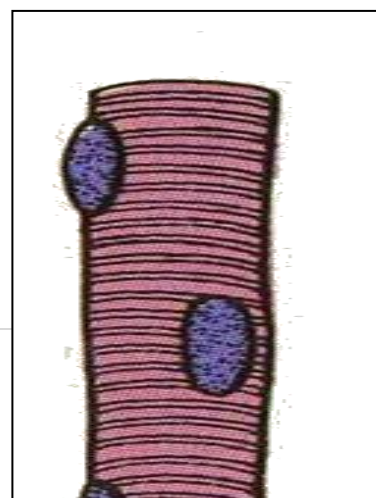
AN INTRODUCTION:

- ▶ 640+ named muscles, 1000+ unnamed
- ▶ Main framework of body is covered by muscles
- ▶ Muscles account for 50% of body weight
- ▶ Definition: - a muscle is a tissue whose cells have the ability to contract, producing movement
- ▶ Muscles always work in pairs
- ▶ Muscles pull, but never push
- ▶ Need a healthy blood and nerve supply
- ▶ A muscle that is contracted whilst lengthening is known as an eccentric contraction.

Types of Muscle Tissue:

VOLUNTARY


- ▶ **Skeletal muscle** – muscles which move the skeleton
- ▶ Also called **striated**
- ▶ Attached to bones by **tendons**



- ▶ Structure – **bundles of fibres**
(each fibre a single cell)
- ▶ Each fibre contains many nuclei
- ▶ Fibres appear long and striped


Under **conscious** control – CNS

INVOLUNTARY

- ▶ **Smooth** muscle
- ▶ Situated in walls of **internal organs** e.g. stomach, blood vessels, eyes
- ▶ Cells are spindle shaped with only one nucleus
- ▶ Cells are unstriated and bound together in sheets 
- ▶ Regulated by the autonomic nervous system
- ▶ Smooth muscle does not tire easily

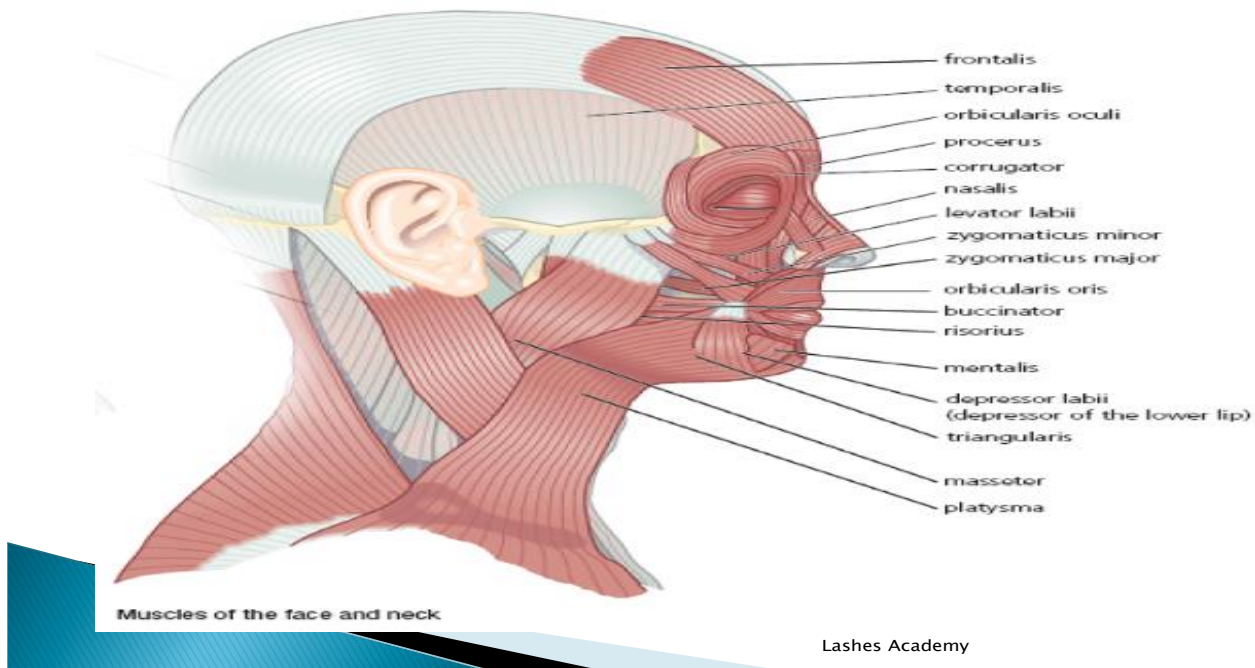
CARDIAC

- ▶ Found in the **heart** – involuntary & striated muscle tissue
- ▶ similar to skeletal muscle but shorter and thicker and form a dense mass – only one nucleus
- ▶ **Contracts rhythmically** (auto rhythmic) without nervous stimulation and does not tire easily



The outermost layer of a muscle is called the **Epimysium**

Muscles of the face and neck

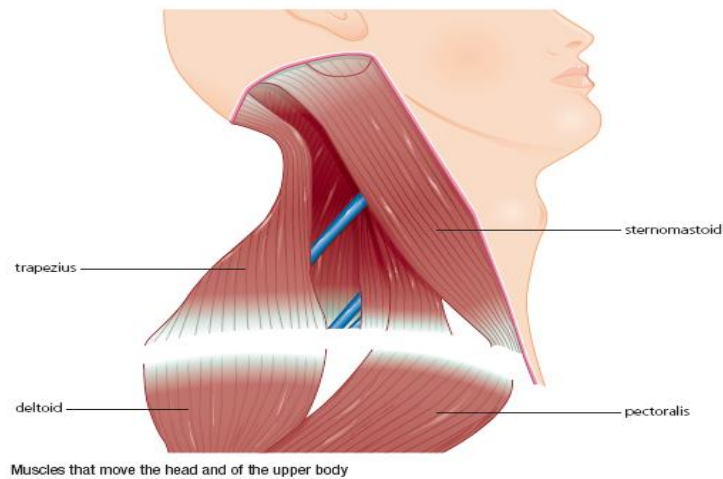


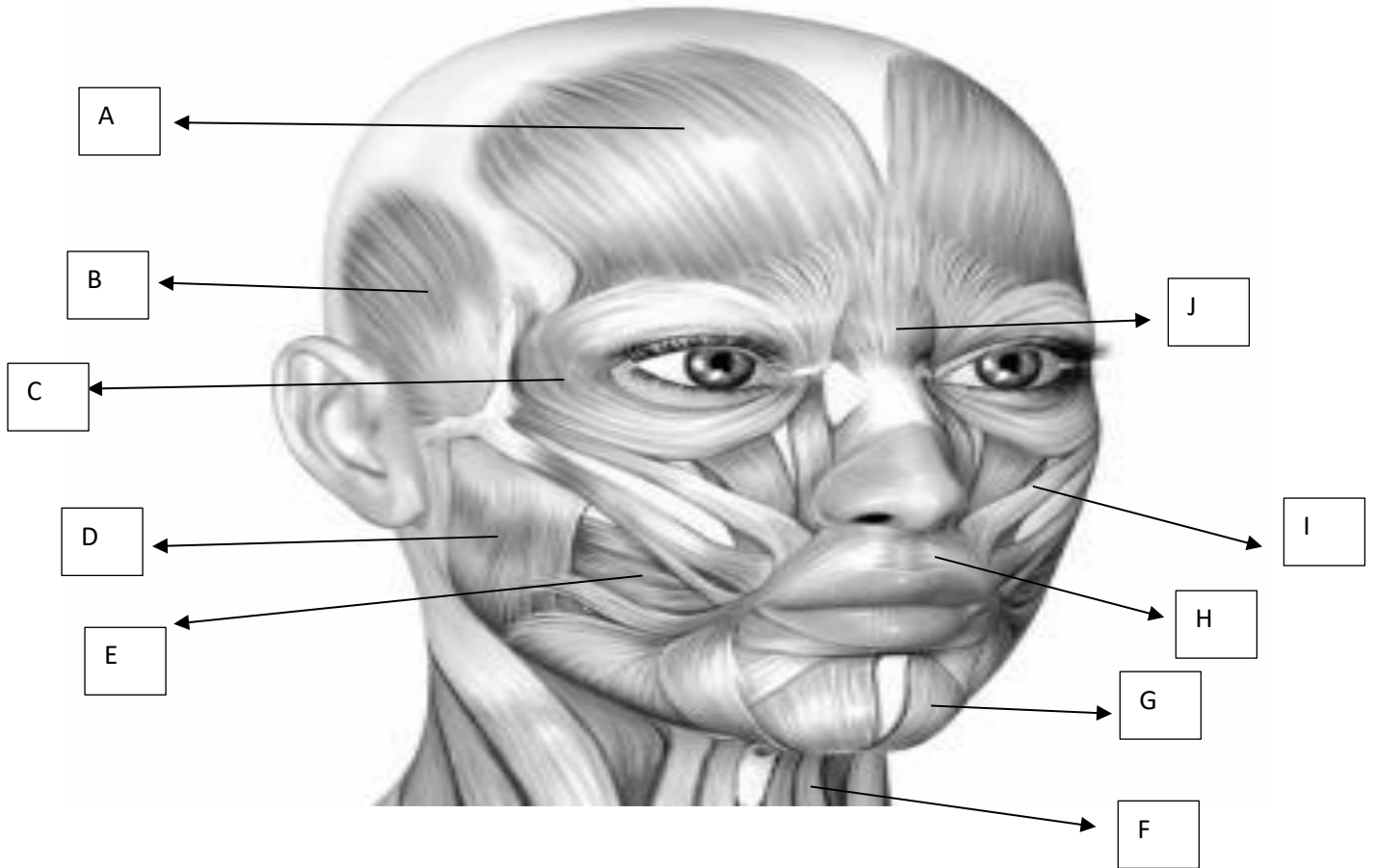
MUSCLES OF FACIAL EXPRESSION

MUSCLE	LOCATION	ACTION
Frontalis	Forehead	Raises brow, wrinkles forehead (look of surprise)
Corrugator	Between the brows	Draws brows down and together (frowning)
Orbicularis Oculi	Surrounds the eyes	Closes the eyelid (blinking, winking)
Risorius	Extends from the corner of the mouth	Draws mouth corners outwards and backwards (smiling)
Buccinator	Inside the cheeks, between jaws	Compresses the cheeks as in sucking and blowing
Zygomaticus (major and minor)	Cheek bone to corner of mouth	Lifts corners of mouth back and upwards (grinning)
Procerus	Covers bridge of nose	Draws down brows and wrinkles bridge of nose
Nasalis	Covers lower nose	Compresses lower nose
Dilator Naris	Nostrils	Flares nostrils
Levators (labii)	Surrounds the upper lip	Raises and draws back the upper lip (sneering)
Depressor labii	Surrounds the lower lip	Pulls down the lower lip to one side
Orbicularis Oris	Surrounds the mouth	Closes the mouth, purses the lips (whistling, kissing)
Triangularis	Corner of lower lips and over chin	Draws down the corners of the mouth (sad)
Mentalis	Covers the front of the chin	Raises lower lip and wrinkles the chin (pouting)
Quadratus labii inferioris	Close to mouth opening	Lifts the upper lip

Platysma	Under chin and down neck	Draws the mouth corners down and back (necklace lines)
MUSCLES OF MASTICATION	LOCATION	ACTION
Masseter	Cheeks	Raises the jaw and clenches the teeth.
Temporalis	Side of temples	Clenches teeth, raises lower jaw and closes mouth
MUSCLES THAT MOVE THE NECK AND HEAD	LOCATION	ACTION
Sterno-cleido-mastoid	Either side of the neck	Flexes the neck, rotates and bows the head
Trapezius	Triangular shaped muscle at upper back and neck	Draws head back and allows movement at the shoulder
Occipitalis	Base of back of head	Draws scalp backwards
MUSCLES OF THE UPPER BODY	LOCATION	ACTION
Pectoralis Major	Front of upper chest	Moves the arm towards the upper body
Deltoid	Top of arm covering shoulder	Takes the arm away from the side of the body

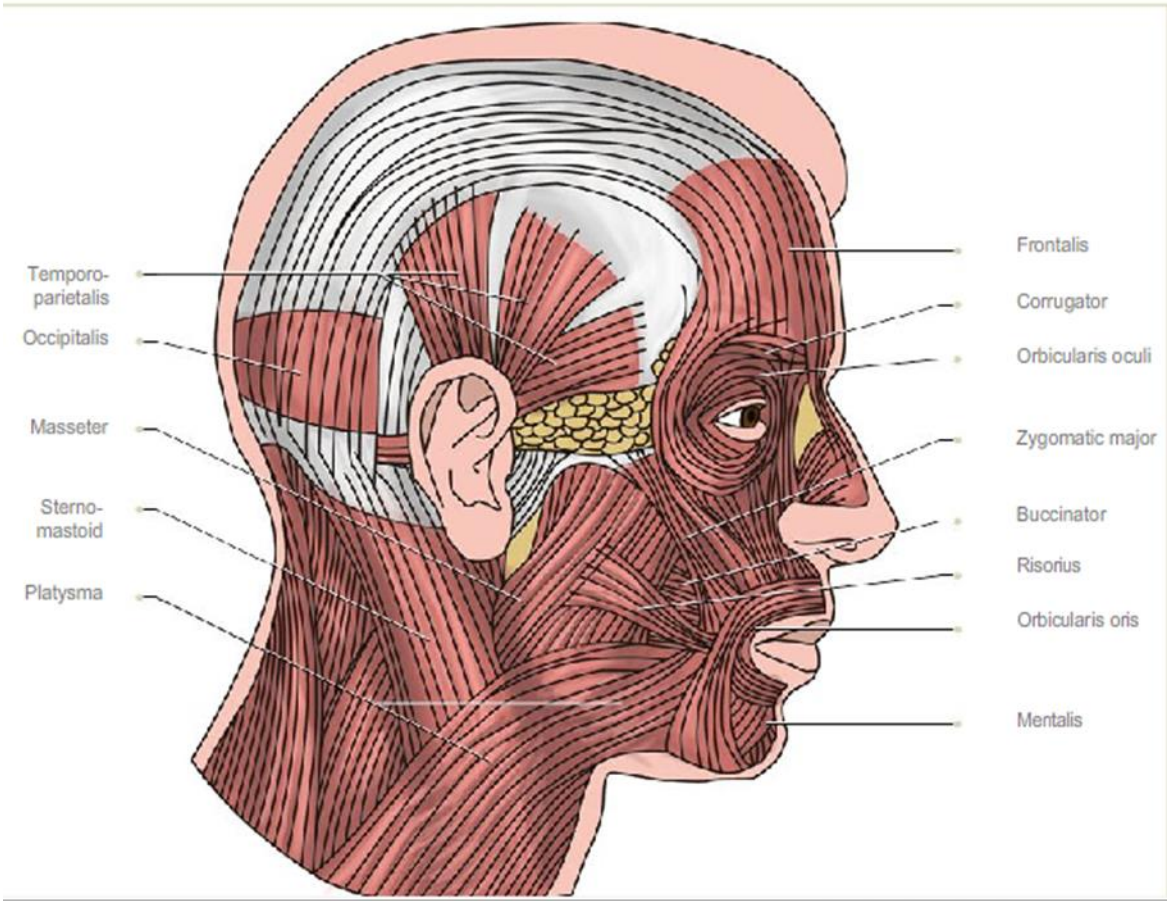
Muscles that move the head and of the upper body





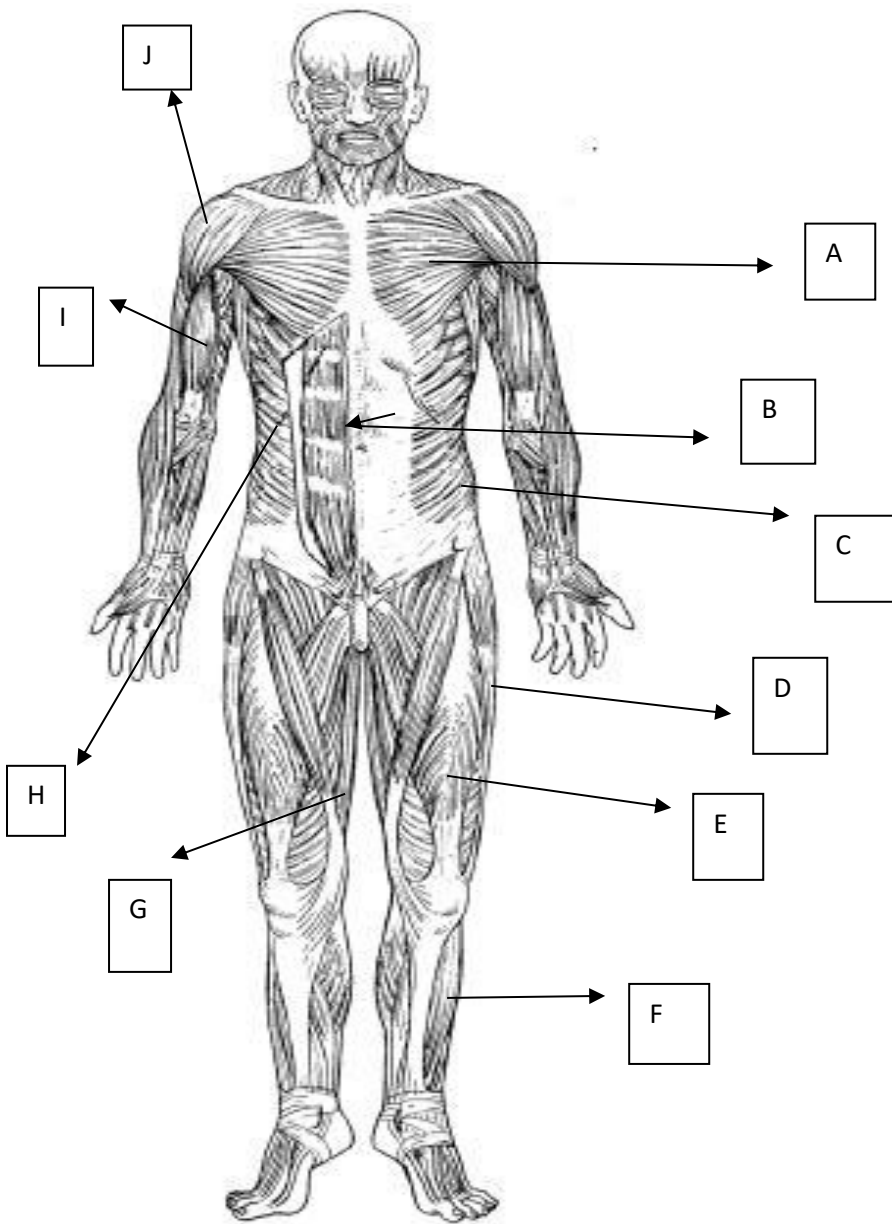
J	Corrugator
E	Buccinator
C	Orbicularis Oculi
H	Orbicularis Oris
I	Zygomaticus
G	Mentalis
B	Temporalis
A	Frontalis
F	Platysma

D	Masseter
---	----------



Revise this picture

MUSCLES OF THE BODY – FRONT VIEW REVISION TEST

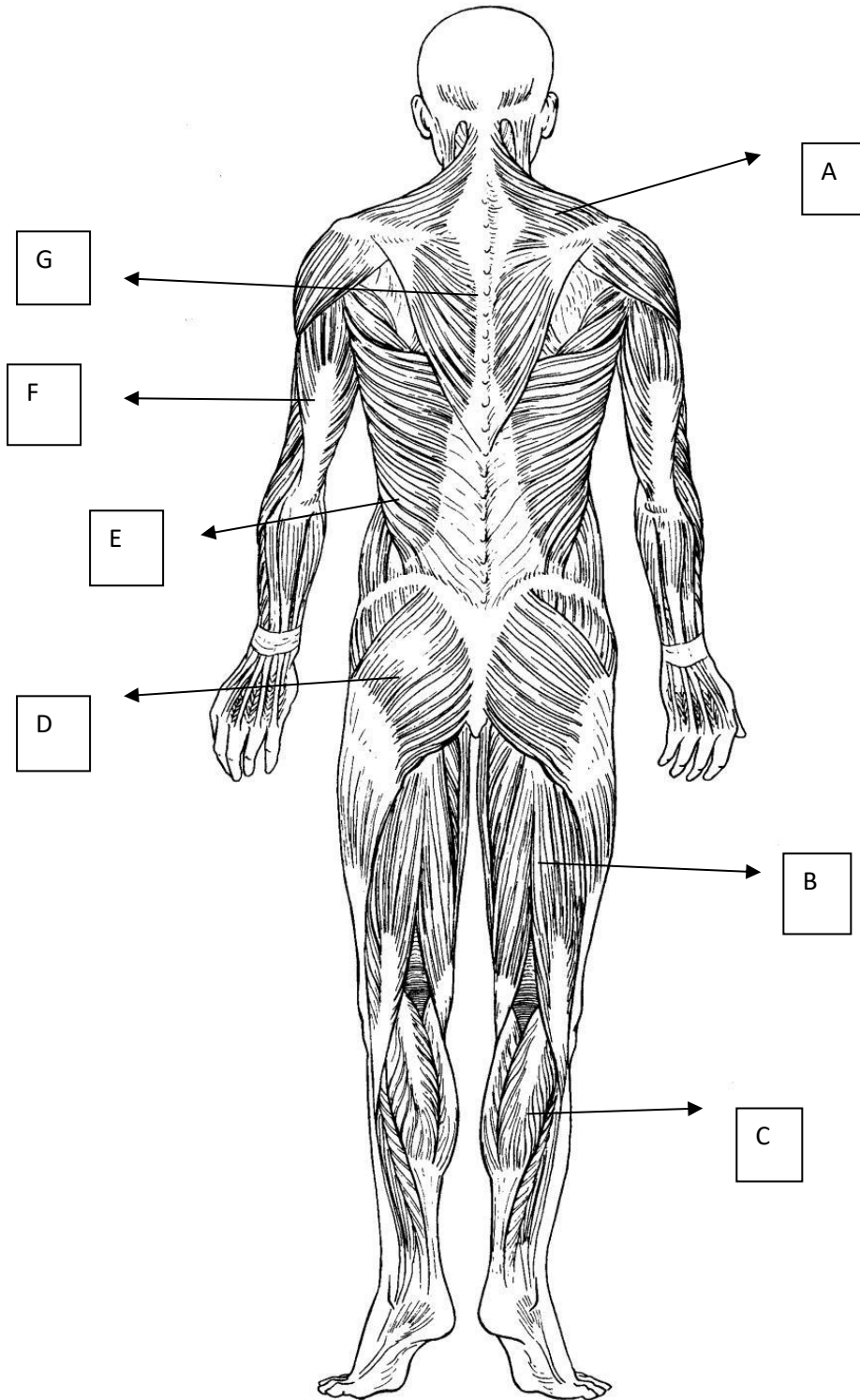


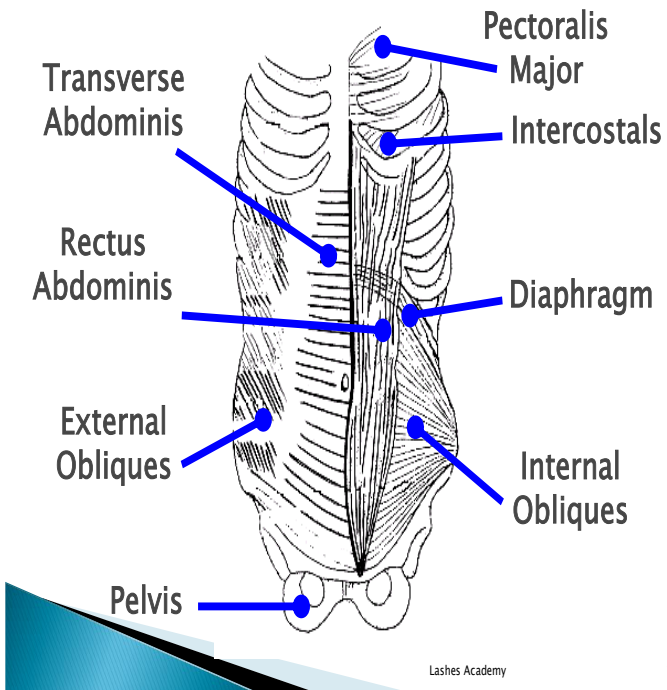
1	J	Deltoid
---	---	---------

2	F	Tibialis Anterior
3	I	Biceps
4	G	Adductors of the thigh
5	H	Intercostals
6	D	Abductors of the thigh
7	E	Quadriceps Extensors
8	C	Obliques
9	A	Pectorals
10	B	Rectus Abdominus

REVISE THIS PICTURE

1	A	TRAPEZIUS
2	E	LATISSIMUS DORSI
3	G	ERECTOR SPINAE
4	B	HAMSTRINGS
5	D	GLUTEALS
6	F	TRICEPS
7	C	GASTROCNEMIUS AND SOLEUS



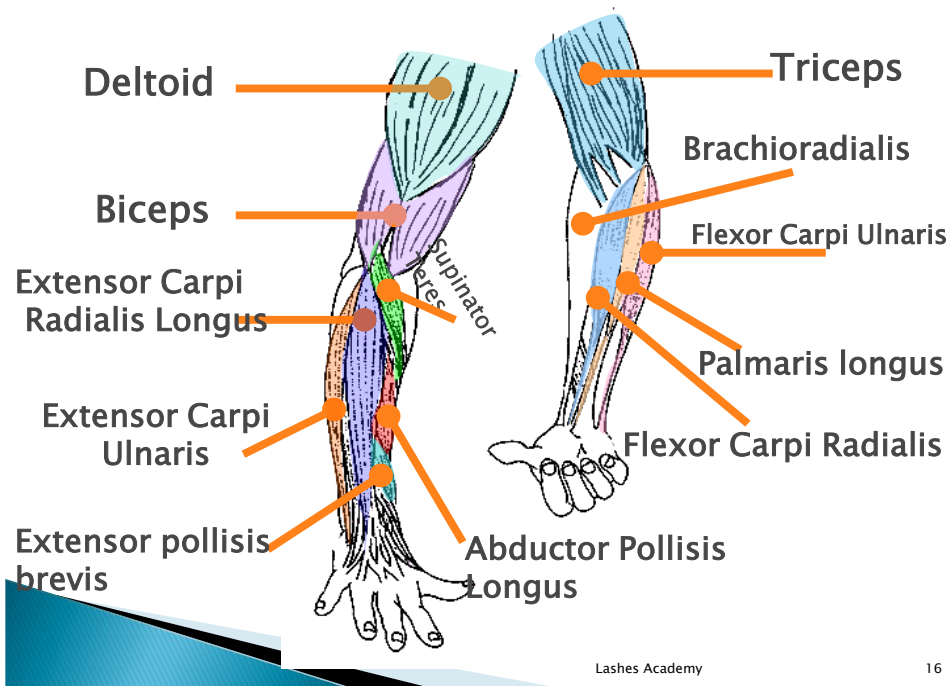


Muscles of the abdomen

- ▶ Rectus abdominus - flexes spine, compresses abdomen, tilts pelvis upwards
- ▶ Obliques - compresses abdomen and twists the trunk
- ▶ **Diaphragm – has an integral part in inspiration and expiration.**

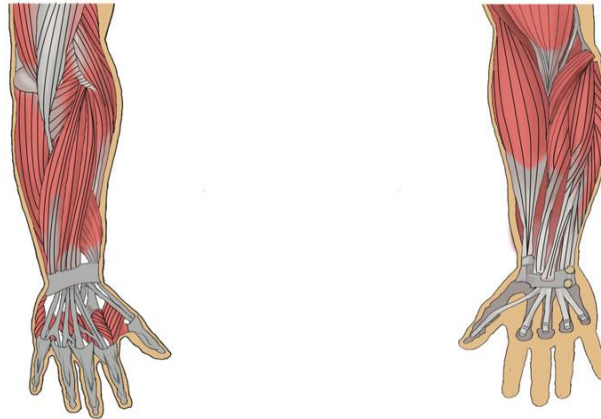
Lashes Academy

14



Lashes Academy

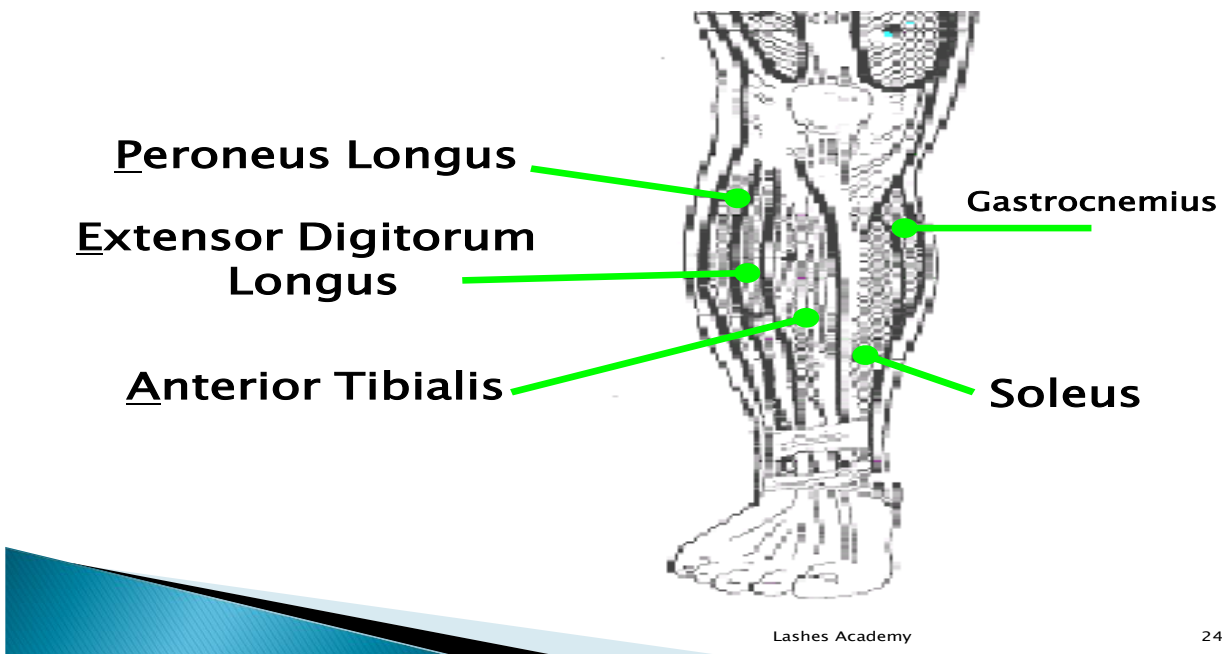
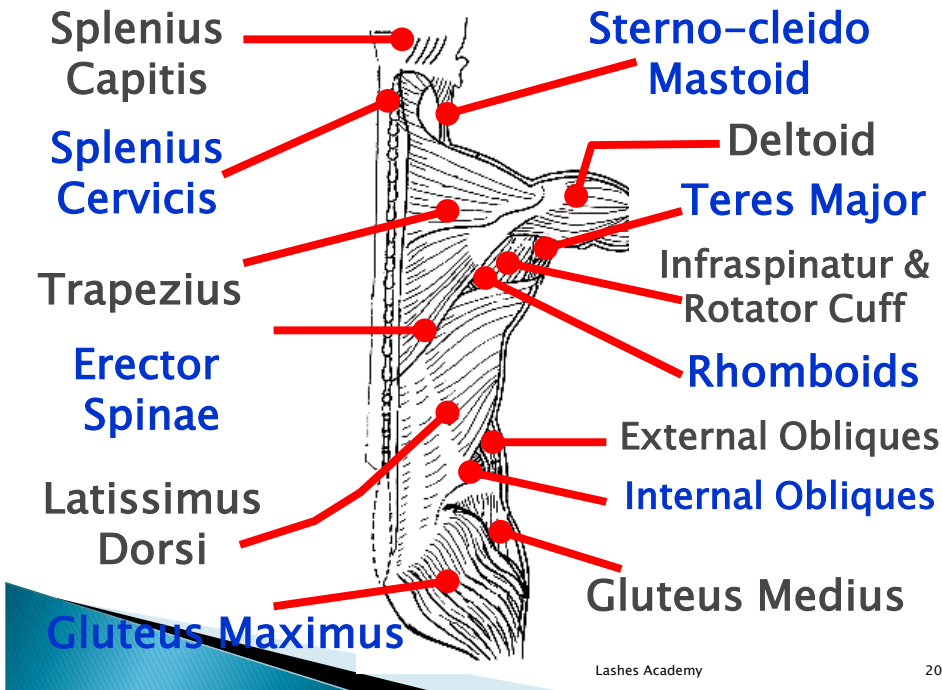
16



A	Triceps Brachil	G	Forearm extensors
E	Biceps Brachil	C	Forearm flexors
F	Brachialis	D	Wrist extensors
I	Brachioradialis	B	Wrist flexors
H	Pronator teres		

Muscles of chest and upper arm

- ▶ **Pectoralis major** - moves the arm towards the upper body
- ▶ **Pectoralis minor** - draws shoulder downwards and forwards
- ▶ **Deltoid** - takes the arm away from the side of the body
- ▶ **Biceps** - flexes the elbow, supinates the forearm and hand
- ▶ **Triceps** - extends the elbow
- ▶ **Brachialis** - flexes the elbow
- ▶ **Brachioradial** - flexes the arm at the elbow
- ▶ **Flexors** - flexes and adducts the wrist, drawing it towards the forearm
- ▶ **Extensors** - extends and abducts the wrist and hand
- ▶ **Thenar muscles** - flexes the thumb and moves it outwards and inwards
- ▶ **Hypothenar muscles** - flexes little finger and moves it outwards and inwards



- ▶ **Gluteals** - abducts and rotates the femur
- ▶ **Hamstrings** - flexes the knee, extends the thigh
- ▶ **Gastrocnemius** - flexes the knee, plantar-flexes the foot
- ▶ **Soleus** - plantar-flexes the foot

- ▶ **Quadriceps extensor** - extends the knee, flex the hip as in kicking
- ▶ **Sartorius** - flexes the knee and hip, abducts and rotates the femur, used to sit cross-legged
- ▶ **Adductors** - adducts the hip, flexes and rotates the femur
- ▶ **Tibialis anterior** - inverts the foot, dorsi-flexes the foot, rotates foot outwards

FUNCTIONS OF THE MUSCULAR SYSTEM:

Heat Production

- ▶ The contraction of skeletal muscles produces heat, which is transported around the body by the blood.

Shape

- ▶ Muscles cover the skeleton and gives the body a rounded shape

Movement

- ▶ Skeletal muscles attached to bones by tendons produce movement of the skeleton
- ▶ Internal organs contain muscle to produce movement e.g. Eyes, digestive tract, heart.

Posture

- ▶ Muscle tone is responsible for maintaining an upright posture

Four main characteristics of muscle tissue:

- ▶ **CONTRACTIBILITY**
able to shorten and thicken (contract)
- ▶ **EXTENSIBILITY**
can be stretched when relaxed
- ▶ **ELASTICITY**
able to return to its original shape after contraction or extension
- ▶ **EXCITABILITY**
responds to stimuli from nerve impulses

A motor unit is a motor neuron and all of the muscle fibres that it stimulates.

Muscle work in pairs to produce movement. They are known as antagonistic pairs, when one muscle contracts its opposite muscle relaxes. The contracting muscle is known as the prime mover or agonist and the relaxing muscle is known as the antagonist. The quadriceps and hamstrings in the leg and the biceps and triceps in the arm are examples of antagonistic pairs



A	Relaxed biceps	B	Contracted biceps
D	Contracted triceps	C	Relaxed triceps

Muscle Tone


- ▶ All skeletal muscles covering the body are kept in a partly contracted state known as muscle tone, by a steady flow of nerve impulses from the spinal cord.
- ▶ Some of muscle fibres are contracted and some are relaxed at the same time.
- ▶ If a muscle loses its nerve supply, it will Atrophy and lose around two-thirds of its bulk within a few months.
- An increase of muscle fibre diameter is called muscle hypertrophy.
- Many of the diseases affecting muscles, such as poliomyelitis are really diseases of the nervous system rather than the muscular system.
- Muscles tend to suffer injury rather than disease generally and are capable of self-repair.
- If a muscle is partially destroyed the remaining part will grow larger and stronger to compensate.
- The outermost layer of a muscle is called Epimysium.
- ▶ A relaxed muscle is never really completely relaxed – there are always a few muscle fibres, which remain contracted to give a muscle a certain degree of firmness.

ORIGIN

- ▶ The point to which a muscle is attached to a bone and **does not move**.

INSERTION

- ▶ The point to which a muscle is attached to a bone and **does move**.



NERVOUS SYSTEM

Homeostasis

- ▶ The body is made up of millions of tiny living units called cells.
- ▶ Cells are organised into organs.
- ▶ To work efficiently cells, need stable, balanced conditions.
- ▶ Keeping a constant internal environment within the body is called homeostasis.

This is achieved by 2 systems;

- ▶ **Endocrine system** – produces hormones – **slow** acting
- ▶ **Nervous system** – detects changes in homeostasis and sends messages through nerve impulses to restore balance – **fast** acting

NOTE: The 2 ions which are necessary for the transmission of a nerve impulse are sodium and potassium. Nerve impulses are transmitted electrochemically.

The part of a nerve cell that carries impulses away from the cell is an axon.

FUNCTIONS:

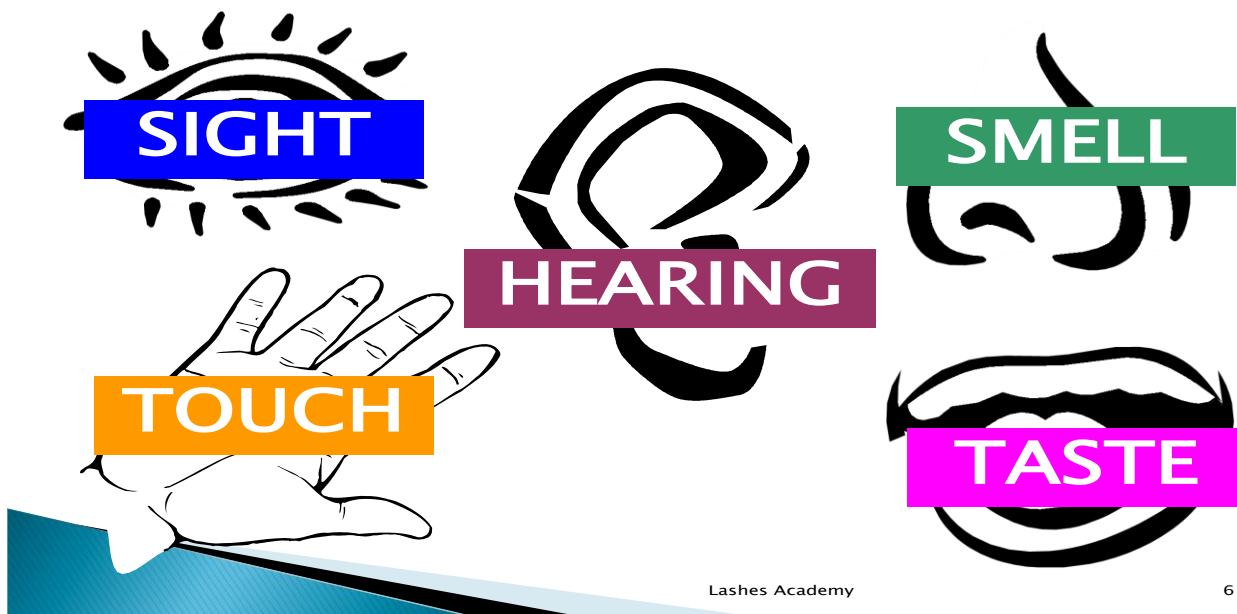
1. **Receiving** sensations from the external and internal environments.
2. **Storing** them, thinking about them, associating them with other impressions and remembering them.

3. **Acting** upon them by sending messages to the muscles, endocrine glands and other organs.

1. RECEIVING / SENSING

- ▶ The nervous system senses change inside and outside of the body
- ▶ These changes are called stimuli
- ▶ Stimuli are detected by special cells called receptor cells
- ▶ Receptor cells are often grouped in sensory organs, such as the eye
- ▶ Other sense organs are found in the skin such as pain receptor cells

The Nervous System – The Senses



2. STORING / ANALYSING

- ▶ Once a change has been sensed, the next step is to analyse the information and decide what to do with it.
- ▶ The central nervous system (CNS) deals with these processes.
- ▶ Information from receptors to the CNS are transmitted by nerve impulses.
- ▶ The information may be stored in our memory or may need an instant response.

3. ACTING

- ▶ If a message needs a response, nerve impulses are sent to an effector organ.
An effector is an organ which carries out an action.

- ▶ An effector is a muscle or a gland.

The nervous system is divided into two parts:

1. THE CENTRAL NERVOUS SYSTEM

Brain

- ▶ controls consciousness, emotions, thought, movement and unconscious body functions

Spinal Cord

- ▶ allows communication between brain and nerves leaving the cord centre for reflex action

The cerebrum:

- ▶ This is the largest part of the brain
- ▶ Divided into two hemispheres (left & right)
- ▶ The outer layer is made of folds of grey matter (i.e. Cell bodies)
- ▶ Inside the grey matter is white matter (i.e. Nerve fibres)
- ▶ These fibres connect different parts of the brain together.
- ▶ Controlling voluntary movements.
- ▶ Interpreting conscious sensations like pain, heat & cold.
- ▶ Controls mental activity, memory, intelligence, and reasoning.

Cerebellum

- ▶ Also known as the small brain.
- ▶ Positioned below the cerebrum and over the medulla oblongata.
- ▶ It co-ordinates muscular activity
- ▶ Subconsciously maintaining muscle tone & posture
- ▶ Maintains balance, co-ordination and equilibrium of body.

Hypothalamus

- ▶ Situated at the base of the mid brain, it forms the floor of that part of the section
- ▶ Helps with regulation of body temperature, water balance and metabolism
- ▶ Centre for emotion such as thirst, appetite, sex, pain and pleasure.
- ▶ It also regulates the pituitary gland.

The meninges:

- ▶ The meninges are membranes which protect the whole of the central nervous system. There are three different layers:

Dura mater:

- ▶ A double layer of tough, fibrous membrane forms the outer layers of the skull.

Arachnoid mater:

- ▶ Delicate membrane positioned immediately under the dura and above the pia mater. It merges with the dura mater and covers the spinal cord as far as the sacrum.

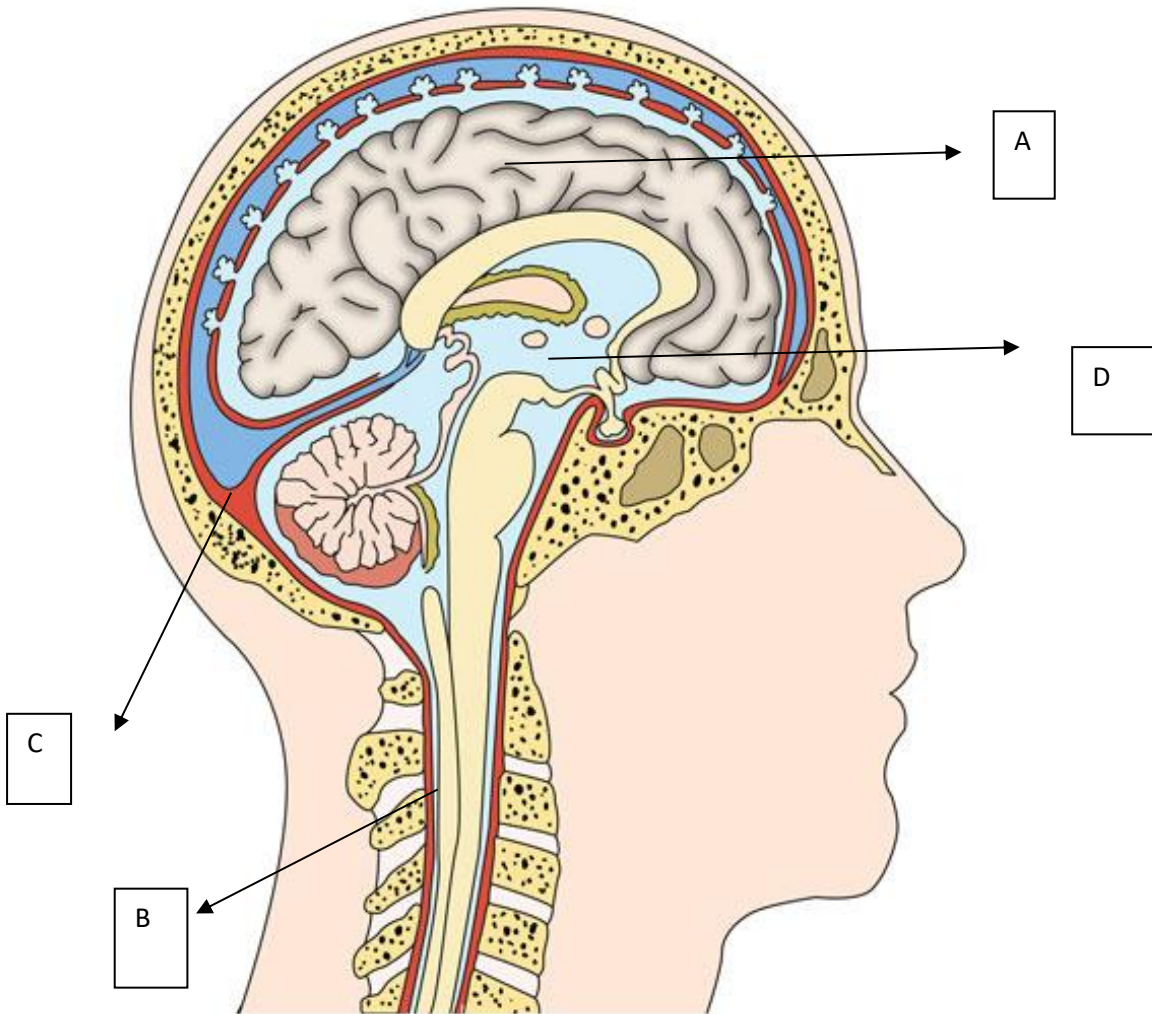
Pia mater:

- ▶ A thin vascular membrane which closely covers the brain.
- ▶ It supplies blood to the brain and spinal cord.

Cerebrospinal fluid:

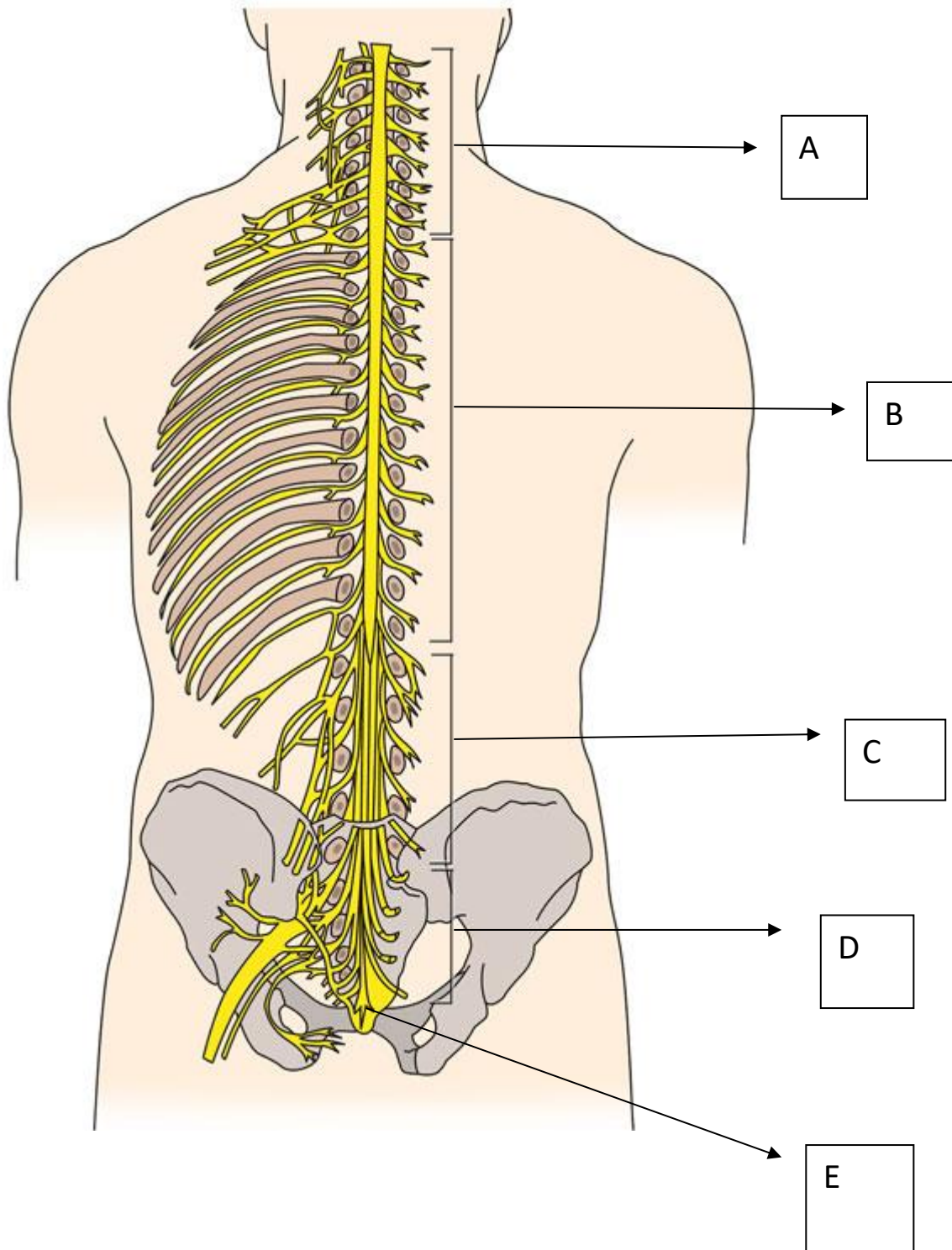
- ▶ This is clear, colourless fluid, formed in special cells.
- ▶ It resembles blood plasma in composition.
- ▶ It protects the brain and spinal cord, forming a cushion between the bony cavities and the nerves acting as a shock absorber.
- ▶ Keeps pressure around the brain and spinal cord constant.

STRUCTURE OF THE BRAIN



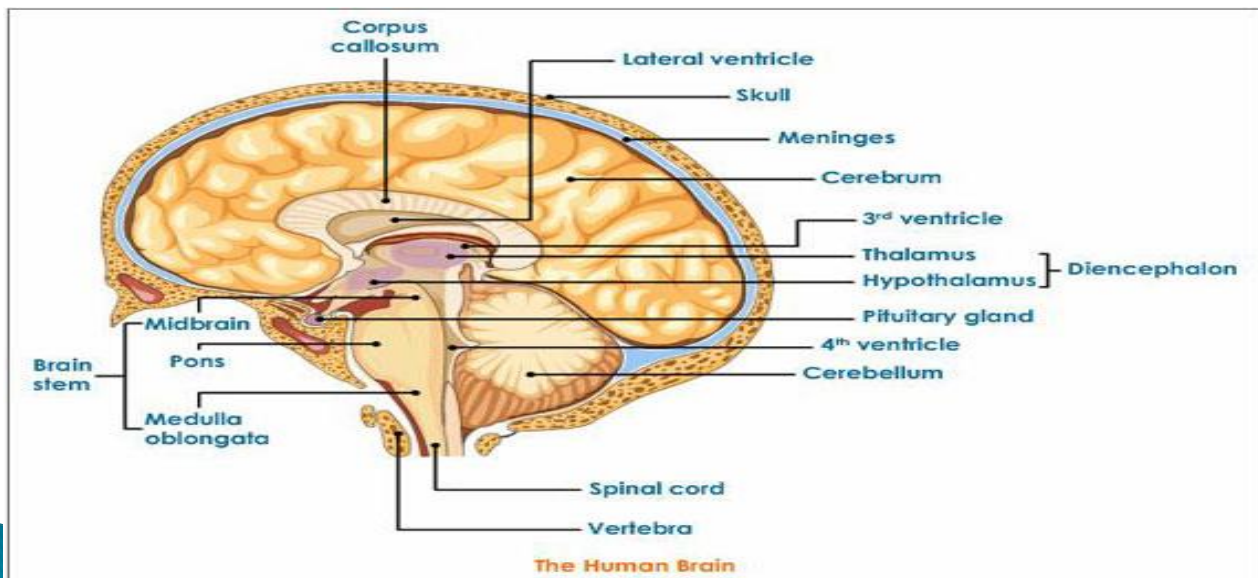
A	Brain	B	Spinal Cord
D	Cerebrospinal fluid	C	Meninges

SPINAL NERVES



E	Coccygeal – This nerve supplies the skin in the coccyx area.
A	Cervical – These nerves supply the back of the head, neck, shoulders, arms and back.
D	Sacral – they supply the thighs, legs, buttocks, feet anal and genital areas.
C	Lumbar – they supply the muscles in the external genitals, groin and lower limbs.
B	Thoracic – These nerves supply the muscles, abdomen and thorax.

Central Nervous System



Lashes Academy

16

Brain stem:

The brain stem consists of three parts:

Midbrain:

Structure:

- ▶ Lies between cerebrum and cerebellum above pons Varoli.
- ▶ About 2cm long and consists of nerve cells and fibres

Function:

- ▶ The relay station of the brain, transmitting messages to and from the spinal cord, the cerebrum and cerebellum.

Pons varoli

Structure:

- ▶ It consists of nerve fibres bridge (pons in Latin means bridge) the gap between the two hemispheres of the cerebellum.

Function:

- ▶ Like midbrain transmits messages to and from spinal cord and cerebrum.

Medulla Oblongata:

Structure:

- ▶ Lowest part of the brain stem.
- ▶ It controls the actions of the heart and lungs.

Function:

- ▶ Cardiac centre, respiratory centre, reflex centre.

THE PERIPHERAL NERVOUS SYSTEM (PNS)

Cranial Nerves – 12 x pairs = attached to brain

- ▶ concerned with head, neck, face
- ▶ take impulses to and/or from the brain
- ▶ motor, sensory and mixed nerves

Spinal Nerves – 31 x pairs = attached to cord

- ▶ take impulses to and from spinal cord
- ▶ mixed nerves

Autonomic Nervous System (ANS)

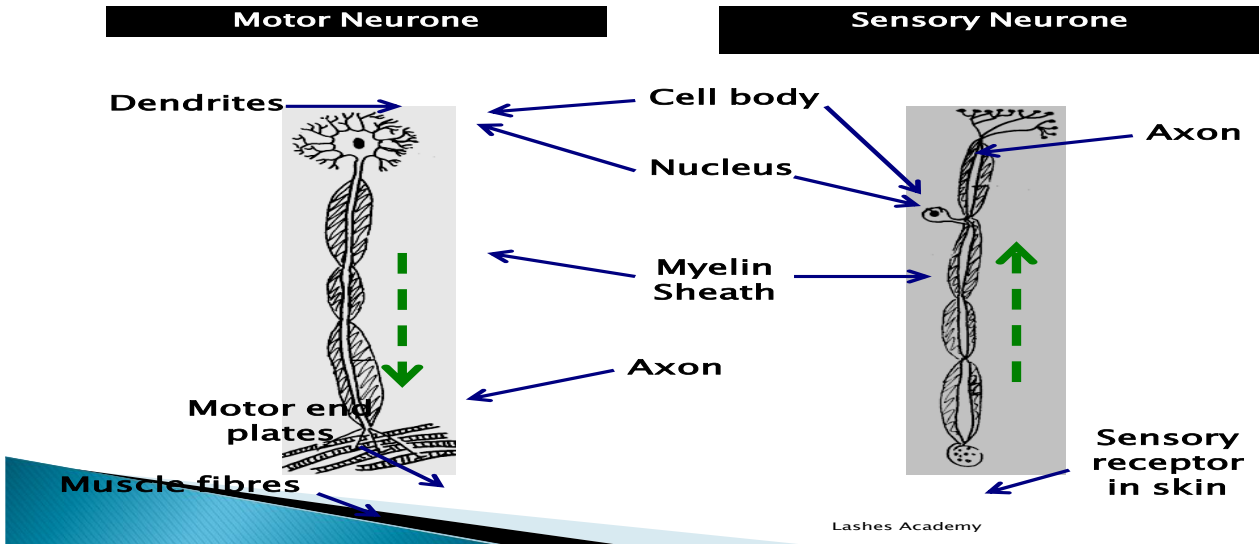
- ▶ Controls functioning of internal organs without the need for conscious control (2 x parts)

Sympathetic:

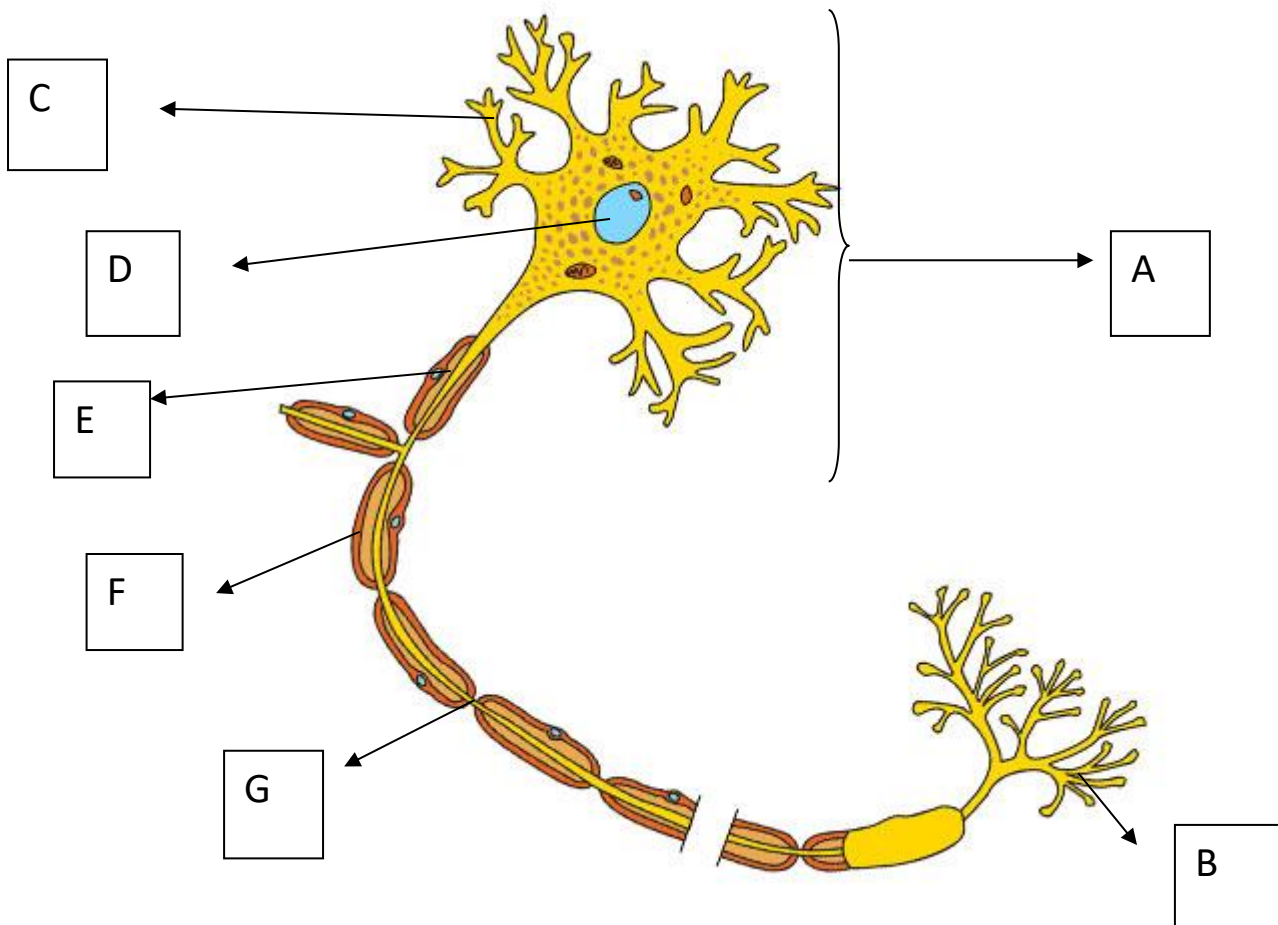
- ▶ Stimulates actions of organs.
- ▶ Release noradrenaline which prepares the body for excitement and stress (fight or flight syndrome)

Parasympathetic

- ▶ Slows down actions of organs to that produced by sympathetic nerves.



STRUCTURE OF A NEURONE



C	Dendrite
A	Cell body
G	Node of Ranvier
B	Synaptic knob
D	Nucleus
E	Axon
F	Myelin sheath

Nerve cells

Nerve cells are the basic unit the system on which everything else is built.

- ▶ **Cell body** – the centre of the neurone, with a nucleus and cytoplasm.
- ▶ **Dendrites** – nerve fibres, like branches, which transmit nerves impulses to the cell body.
- ▶ **Axon** – a long single nerve fibre, **which transmits or carries nerve impulses away from the nerve body (cell)**; neurones generally have only one axon.

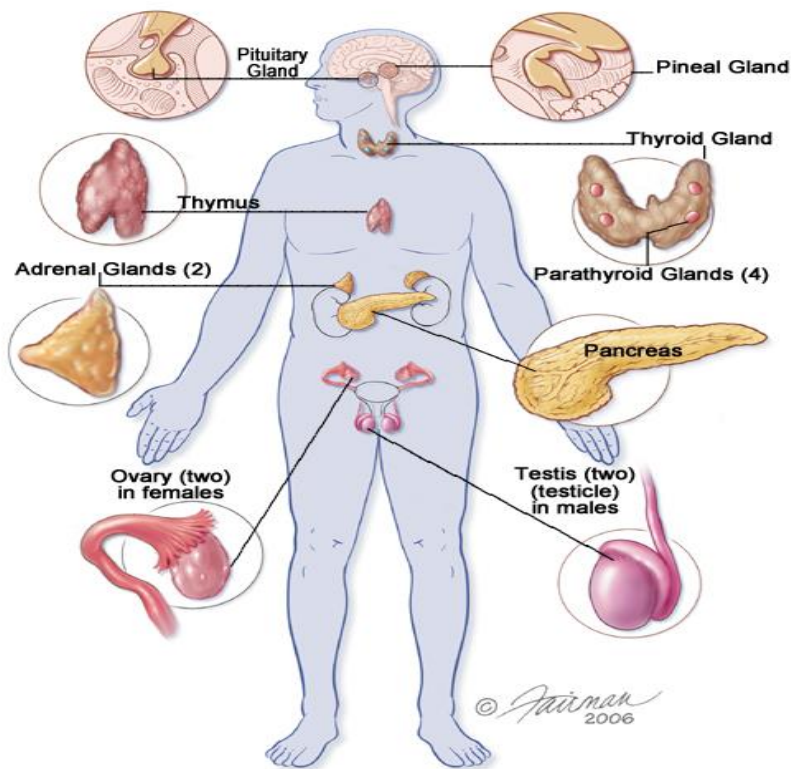
- ▶ **Myelin sheath** – made of white, fatty substance, this sheath covers the axon, protects it from pressure and helps speed up nerve conduction (the speed at which messages are transmitted).
- ▶ **Neurilemma** – a fine, delicate membrane which surrounds axons and helps regenerate nerve cells; only found in peripheral nerves and not in the brain of spinal cord.
- ▶ **Nodes of Ranvier** – these are compressed points in the myelin sheath along the nerve. They speed up the passage of nerve impulses along the fibre.
- ▶ **Axon terminals** – ends of the tiny fibres that make the axon are expanded and called end feet or axon terminals.
- ▶ **Synapse** – the point where one neurone meets another.
- ▶ A chemical that transmits impulses across synapses from one nerve to another is a **neurotransmitter**

THE ENDOCRINE SYSTEM

- ▶ **The function of the endocrine system is to produce hormones and secrete them directly into the bloodstream where they are carried to their target organs - specific glands, organs or tissues where they have a particular effect**

The endocrine glands

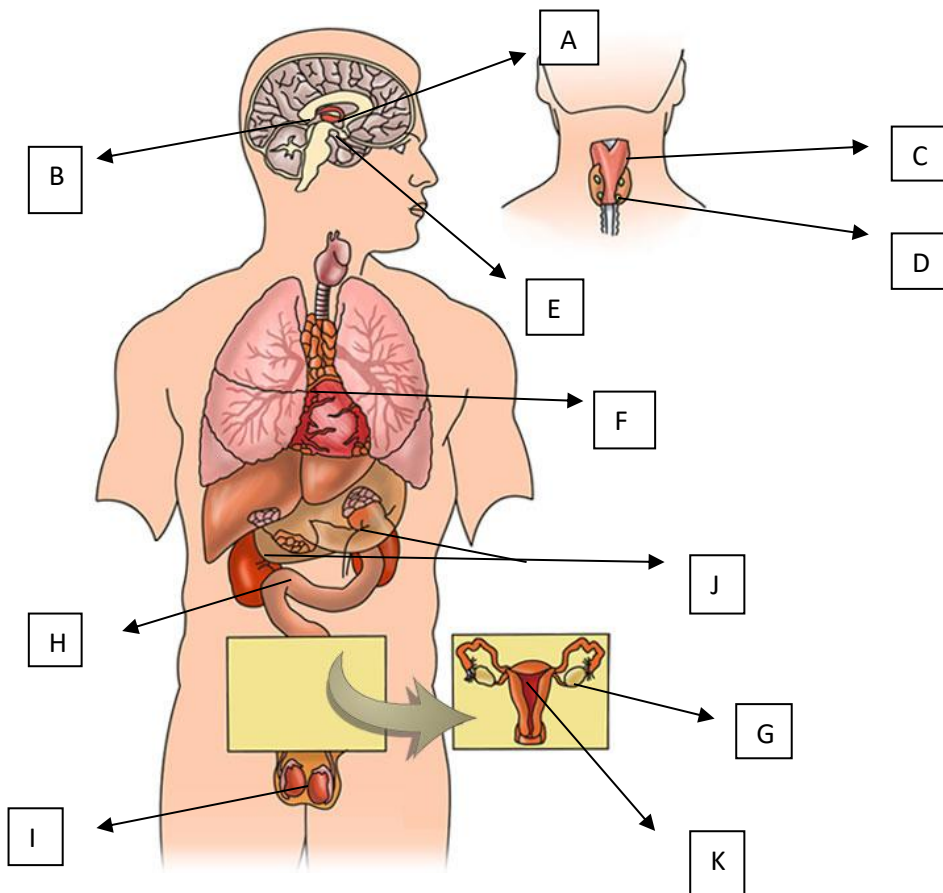
- ▶ **Pituitary gland**
- ▶ **Thyroid gland**
- ▶ **Parathyroid gland**
- ▶ **Pancreas (Islets of Langerhans)**
- ▶ **Adrenal glands**
- ▶ **Ovaries**
- ▶ **Testes (gonads)**



The endocrine system is composed of the following endocrine glands; thyroid, parathyroid, pituitary, pineal and adrenal. The endocrine glands secrete hormones, which are messenger molecules, into the interstitial fluid in the bloodstream. These released hormones affect nearly every cell, organ, and function of the human body. The endocrine system influences emotional behaviour, growth, development, tissue and sexual function, metabolic rate and reproductive system. Other organs and tissues containing cells that secrete hormones are the stomach, placenta, small intestine, heart, skin, thymus, adipose tissue, kidneys, pancreas, liver, hypothalamus, testes and ovaries.

In general, the endocrine system responses are slower and therefore control processes that happen more slowly than the nervous system. For example, the endocrine system influences things like cell growth, whilst faster processes, like breathing are controlled by the nervous system.

The nervous and endocrine systems are different systems, yet are complementary systems and work together to help the body function properly.

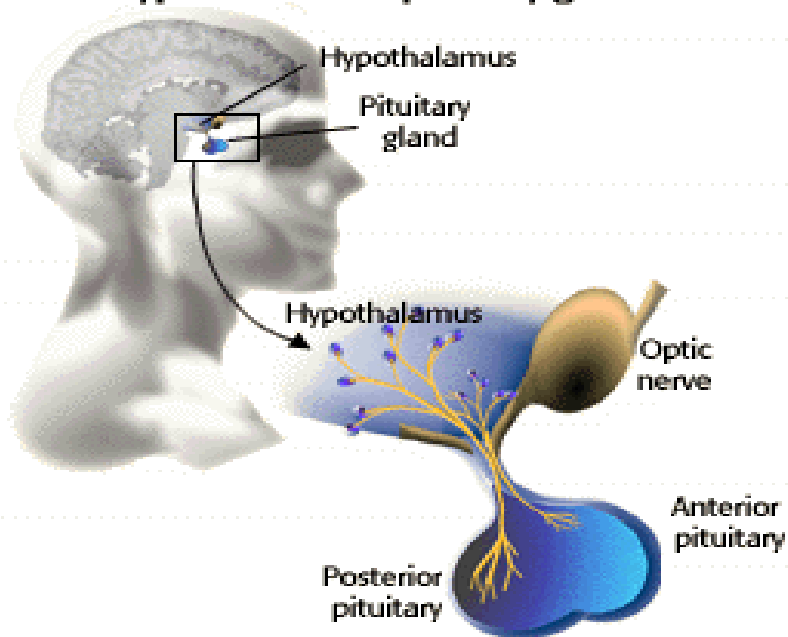


1	C	Thyroid gland	7	J	Adrenal glands
2	D	Parathyroid gland	8	H	Pancreas
3	B	Pineal gland	9	I	Testes
4	A	Hypothalamus	10	K	Uterus
5	E	Pituitary gland	11	G	Ovary
6	F	Thymus			

The pituitary gland

- ▶ The pituitary gland is known as the master gland
- ▶ It is situated in the brain and is attached to the hypothalamus
- ▶ It consists of two lobes – anterior and posterior
- ▶ The hypothalamus acts as a link between the endocrine system and the nervous system.

Hypothalamus & pituitary gland



The pituitary hormones

Anterior lobe hormones

- ▶ **Somatotropic hormone** (growth hormone). Affects the height to which we grow and aids mobilisation of fats to replace glucose when needed by the body.
- ▶ **Thyrotrophic hormone.** Affects activity and growth of the thyroid gland
- ▶ **Adreno-corticotrophic hormone.** Affects release of hormones from the adrenal gland
- ▶ **Gonadotrophic hormones.** Consists of **follicle stimulating hormone** which affects maturation of ovum. **Lutenising hormone** which causes ovulation. **Prolactin (lactogenic) hormone** which affects production of milk after childbirth

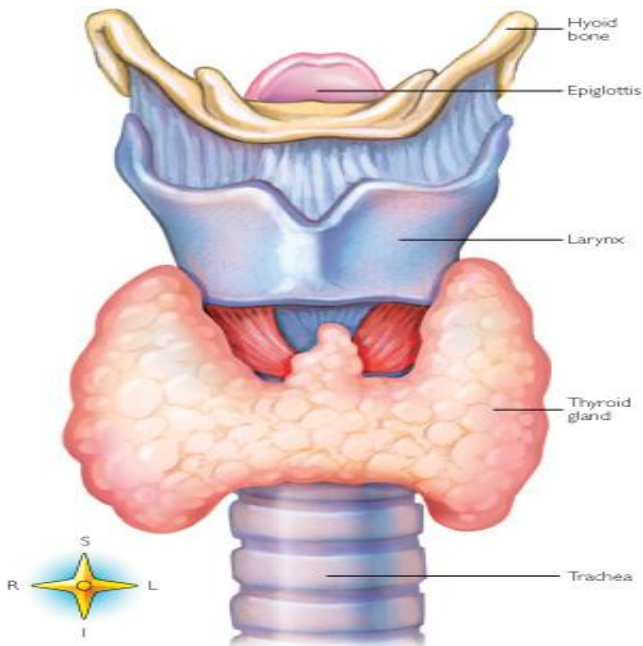
Posterior lobe hormones

- ▶ **Oxytocin hormone** which causes the contraction of the uterus during childbirth and ejection of milk after childbirth
- ▶ **Vasopressin- antidiuretic hormone** which increases water re-absorption from urine formed by the kidneys, thereby concentrating it

The thyroid gland

- ▶ The thyroid gland is situated on the front and sides of the windpipe just below the pharynx
- ▶ It is the largest of the endocrine glands
- ▶ The activity of the thyroid gland is affected by the thyrotrophic hormone from the pituitary gland

- ▶ The function of the thyroid gland is to produce thyroxine and control the body's metabolic rate.



The thyroid hormones

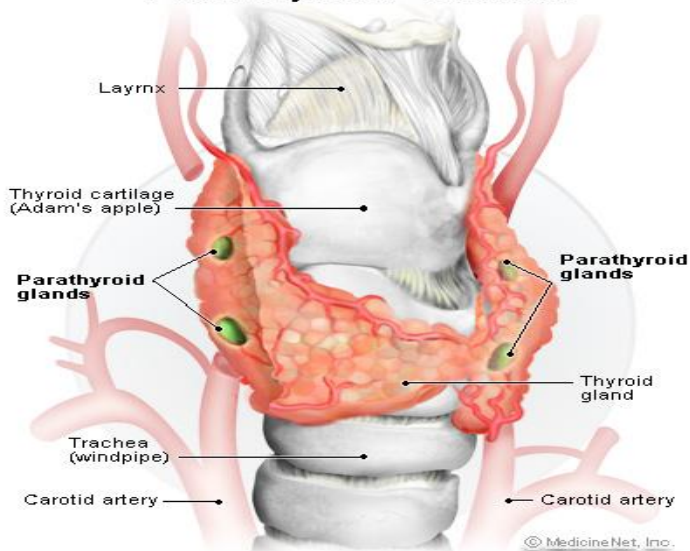
Thyroxine hormone. The body requires the mineral **iodine** to make **thyroxine**. Affects all tissues of the body. Mental and physical development and our irritability. It also affects our basal metabolic rate (bmr). The bmr is the minimal amount of energy that the body needs to maintain vital processes i.e. breathing. It controls how fast cells use energy which affects body weight. It stimulates our use of protein and decreases the calcium in our blood.

- ▶ **Calcitonin hormone** is the hormone that regulates the amount of calcium in our blood. Calcium is needed for healthy bones but also helps with blood clotting and aids the work of the muscles and nerves. If calcium levels in the blood drop, it is removed from the bones to top up the blood levels. Calcitonin ensures no calcium is removed from the bones when levels in the blood are high enough

▶ The parathyroid gland

- ▶ There are four parathyroid glands and they are located on the back of the thyroid gland
- ▶ The parathyroid gland works closely with the thyroid gland and is responsible for making hormones
- ▶ The target site for the parathyroid hormone is the bones.

Parathyroid Glands

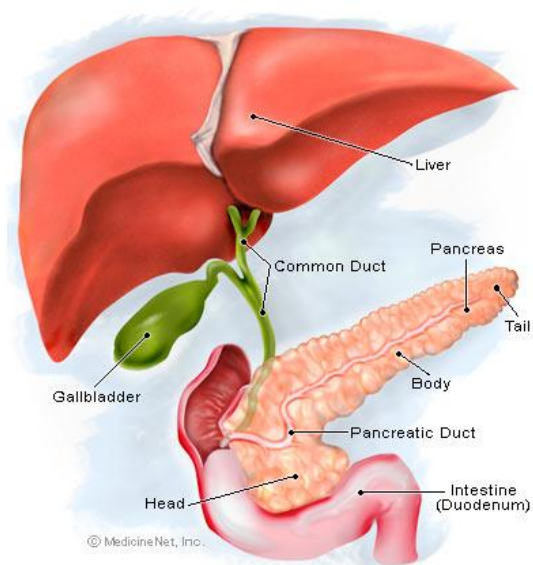


The parathyroid hormones

- ▶ **Parathormone** which is also called **parathyroid hormone (PTH)** has the opposite effect of **thyroxine**. It affects the calcium in the blood by increasing the amount if the levels are too low. This happens when a woman goes through the menopause

The pancreas

- ▶ Known as the Islets of Langerhans
- ▶ Has a head, neck, body and tail
- ▶ Is both an endocrine and an exocrine gland?
- ▶ Keeps blood sugar and glucose at the correct levels
- ▶ Glucose is secreted via the urine if too high
- ▶ It is also a sign of illness

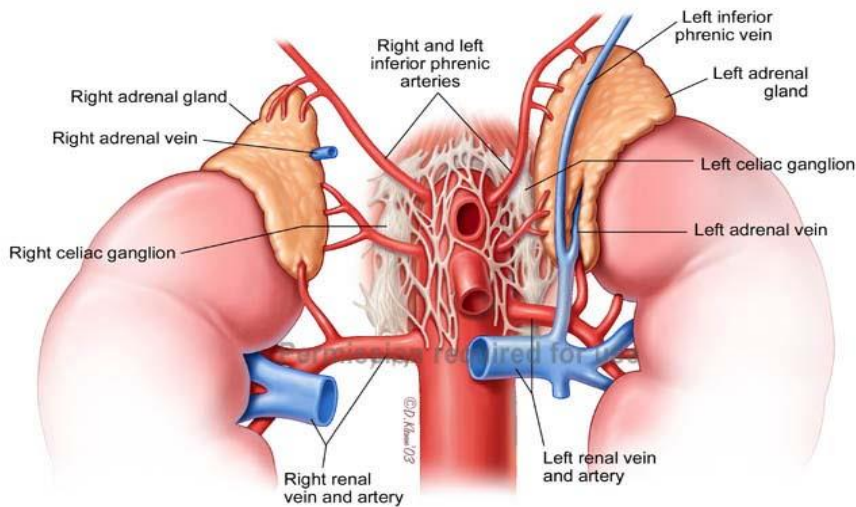


The pancreatic hormones

- ▶ As an endocrine gland the pancreas secretes
- ▶ **Insulin** which decreases blood sugar. Transports glucose into the liver, skeletal muscle and other body cells. Causes glucose to be built up into glycogen in the liver and muscles. In excess is called hyperglycaemia
- ▶ **Glucagon** increases blood glucose. It breaks down glycogen into glucose in the liver. It causes glucose to be released from the liver into the blood. In excess is called hypoglycaemia

The adrenal glands

- ▶ The adrenal glands are situated on the top of each kidney
- ▶ They are triangular in shape
- ▶ They contain two parts – the outer cortex and the inner medulla
- ▶ The adreno-corticotrophic hormone from the pituitary gland affects the hormonal activity of the adrenal glands



The adrenal hormones

- ▶ Adrenal medulla secretes
- ▶ **Adrenaline** increases the heart and breathing rate. Blood vessels in the skin and stomach narrow and the ones in the skeletal muscles widen. Glycogen in the liver is converted to glucose and passed into the blood allowing oxygen and glucose to reach the muscles that need it. Pupils widen and hair is raised making the person look fierce. Responsible for the fight or flight response
- ▶ **Nor-adrenaline** has a similar effect on the body as adrenaline

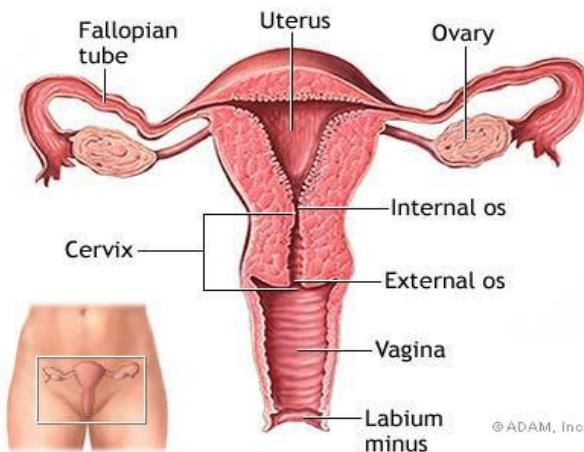
The adrenal cortex secretes 3 steroid hormones consisting of:

- ▶ **Mineral corticoids** whose target organ is the kidneys.
- ▶ **Aldosterone** which makes sure that sodium is passed back into the blood at the kidneys and not excreted in the urine. Sodium and potassium levels are balanced with **aldosterone hormone**. If sodium levels in the blood are low, **aldosterone** is made and if sodium levels are too high **aldosterone** is stopped and sodium is released via the urine.
- ▶ **Glucocorticoids** have many target organs. Two hormones in this group are called
- ▶ **Cortisol** which is the most common, is responsible for ensuring the body has enough energy to cope in times of stress, hunger, injury or fear. It makes sure the brain has a supply of glucose as this is all it can use for respiration, whereas other organs can use other things such as fatty acids or amino acids. It reduces inflammation and controls body rhythms. It is at its lowest levels between 2-4am and rises between 6-9 am so as to wake you up. It then lowers again after lunch and raises in the evening. It makes protein available from the body for cell repair and suppresses production of lymphocytes and the rate at which connective tissue heals itself
- ▶ **Cortison** is the other hormone
- ▶ There are two sex corticoids secreted

- ▶ **Oestrogen** which is produced by both male and females. **Oestrogen** prohibits **parathormone** when women go through the menopause their levels of **oestrogen** drop allowing **parathormone** to pass more calcium into the blood from the bones. This weakens the bones which can lead to them breaking easily. This is called osteoporosis
- ▶ **Androgens** are also produced by both males and females. In females it contributes to sex drive. It is responsible for secondary sexual characteristics at puberty (pubic hair and underarm hair). It affects the pilo-sebaceous unit and can have a masculating effect on women. If too high it can cause male pattern hair growth known as hirsutism

The ovaries

- ▶ These are the female sex organs
- ▶ The ovaries are at the end of the fallopian tubes
- ▶ The ovaries release eggs each month and this process is called the menstrual cycle
- ▶ The uterus walls thicken so that the fertilised egg can grow
- ▶ If the egg is not fertilised the uterus expels the excess lining and this is a menstrual period
- ▶ Some women experience mood swings and/or sore, lumpy breasts and swollen stomach
- ▶ Some women experience pain

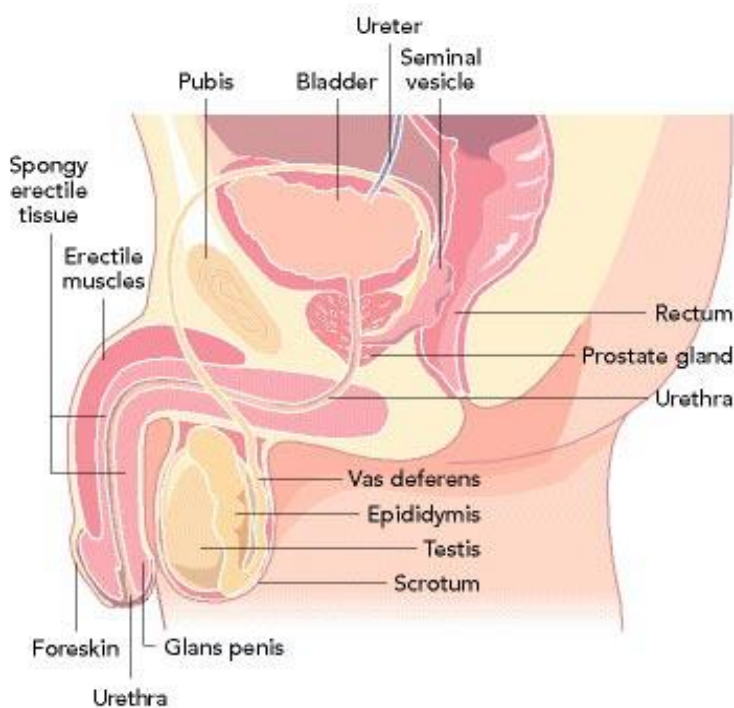


Ovarian hormones

- ▶ **Oestrogen** has many target organs, the main ones being the ovaries and the uterus. **Oestrogen** stimulates the ovum to mature in the ovary. It causes the uterus to thicken during menstruation. It causes secondary sexual characteristics at puberty
- ▶ **Progesterone** targets the uterus and mammary glands. The function of this is to continue the development of the uterus in preparation for the fertilised egg and during pregnancy. It also prepares the mammary glands to secrete milk

The Testes

- ▶ These are the male sex organs
- ▶ They are situated in a sac called the scrotum on the outside of the body beneath the penis
- ▶ The testes produce a steroid hormone



Testicular hormone

- ▶ The testes produce **testosterone** which is a steroid hormone
- ▶ Many target organs are affected by **testosterone**
- ▶ It controls the production of sperm in the testes
- ▶ **Testosterone** stimulates the development of male secondary sexual characteristics
- ▶ Helps to maintain masculinity and fertility

Endocrine Secretions and their Hormones

HORMONES OF PITUITARY GLAND

SECRETION FUNCTIONS

ANTIDIURETIC HORMONE OR VASOPRESSIN

- ▶ Can help to keep blood pressure under control along with aldosterone and enables the kidneys to retain water. Vasopressin helps to control vascular contractions.

CORTICOTROPIN OR ADRENOCORTICOTROPIC



- ▶ Stimulates the adrenal gland into controlling hormone production and secretion.

HUMAN GROWTH HORMONE OR SOMATROPIN

- ▶ Controls overall growth and development of human body cells and stimulates the production of protein.

LUTEINISING HORMONE AND FOLLICLE-STIMULATING HORMONE

- ▶ In females, stimulates secretion of oestrogen and progesterone, ovulation, corpus luteum development. In males, stimulates production of testosterone in testes. It controls specific male and female characteristics like muscles, skin, hair, voice and even personality.

OXYTOCIN

- ▶ Stimulates milk production by the mammary glands and muscles of the uterus to contract.

PROLACTIN

- ▶ Stimulates milk production of the mammary glands.

THYROID-STIMULATING HORMONE OR THYROTROPIN

- ▶ Stimulates production and secretion of hormones by the thyroid gland.

HORMONES OF PARATHYROID GLANDS

SECRETION FUNCTIONS

PARATHYROID HORMONE

- ▶ Controls bone formation and the excretion of calcium and phosphorus.

HORMONES OF THYROID GLAND

SECRETION FUNCTIONS

THYROID HORMONE

- ▶ Regulates the metabolic rate of the body.

CALCITONIN

- ▶ Helps to regulate calcium.

HORMONES OF ADRENAL GLANDS

SECRETION FUNCTIONS

ALDOSTERONE (MINERAL CORTICOID)

- ▶ Helps to maintain salt and water balance. Creates the balance by retaining salt and water and excreting potassium.



CORTISOL (GLOCOCORTICIDS)

- ▶ Enables anti-inflammatory activity and helps to maintain blood pressure, blood sugar level and muscle strength. Also helps to maintain salt and water balance.

ANDROGENS (DEHYDROEPIANDROSTERONE)

- ▶ Influences puberty in both sexes.
- ▶ EPINEPHRINE AND NOREPINEPHRINE
- ▶ Stimulates the lungs, blood vessels, heart and the nervous system.

HORMONES OF PANCREAS

SECRETION FUNCTIONS

GLUCAGON

- ▶ Helps to raise blood sugar levels.

INSULIN

- ▶ Helps to lower blood sugar levels and influences the metabolism of fat, sugar and protein in the body.

HORMONES OF KIDNEYS

SECRETION FUNCTIONS

ERYTHROPOIETIN

- ▶ Stimulates red blood cell production.

CALCITRIOL

- ▶ Helps absorption of dietary calcium and phosphorus.

HORMONES OF OVARIES

SECRETION FUNCTIONS

OESTROGEN

- ▶ Controls the development of female sex characteristics and the reproductive system.

PROGESTERONE

- ▶ The lining of the wall of the uterus is made ready for a fertilised egg to implant itself and the mammary glands get ready to for milk production

RELAXIN

- ▶ Enables greater flexibility of pelvic region during pregnancy and dilates the cervix.



INHIBIN

- ▶ Inhibits secretion of follicle-stimulating hormone.

HORMONES OF TESTES

SECRETION FUNCTIONS

TESTOSTERONE

- ▶ Stimulates the sexual characteristics and the reproductive system of the male.

INHIBIN

- ▶ Inhibits secretion of follicle-stimulating hormone.

HORMONES OF ADIPOSE (FAT) TISSUE

SECRETION FUNCTIONS

LEPTIN

- ▶ Enables appetite control.

HORMONES OF PLACENTA

SECRETION FUNCTIONS

CHORIONIC GONADOTROPIN

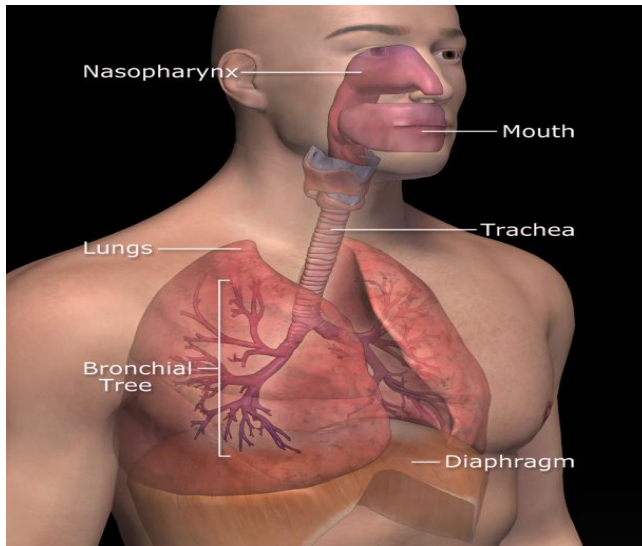
- ▶ Ovaries are stimulated to release progesterone during early pregnancy and to continue the process.

OESTROGEN AND PROGESTERONE

- ▶ Maintains the uterus for readiness for the foetus and placenta during pregnancy.

Acromegaly is caused when there is an over production of the somatrophic hormone by the pituitary gland

The Respiratory System



Anatomy of the Respiratory system

- The respiratory system consists of all the organs that conduct air into the lungs where gas exchange takes place

INSPIRATION

The act of breathing air – Oxygen O₂ into the lungs

EXPIRATION

The act of breathing air – Carbon Dioxide CO₂ out of the lungs

- In order for our bodies to live, grow and repair itself, we need energy, which is taken from the food we eat – the body has first to combine this with oxygen, taken from the air we breathe.
- When we inhale, oxygen enters our lungs and our blood carries it to all the cells in our body.
- Inside each cell energy is released from the combination of oxygen and glucose – this process is called **RESPIRATION**.
- Waste products are produced during this process – Carbon Dioxide and water – which are exhaled from our lungs as we breathe out.
- The lungs are **inert organs** – they have no muscles of their own.
- Muscles between the ribs (external **intercostal**) work with the **diaphragm** to control breathing
- During external respiration, blood loses carbon dioxide and gains oxygen

- The diaphragm is a **dome shaped muscle** situated at the floor of the chest.
- The lungs are contained in the **thoracic cavity**.
- The lungs are surrounded by the **pleural** cavity and membrane which prevent friction.
- A function of the respiratory system is to facilitate the **diffusion** of oxygen into the bloodstream.
- **The structure that serves as a passageway for food and air is the pharynx**

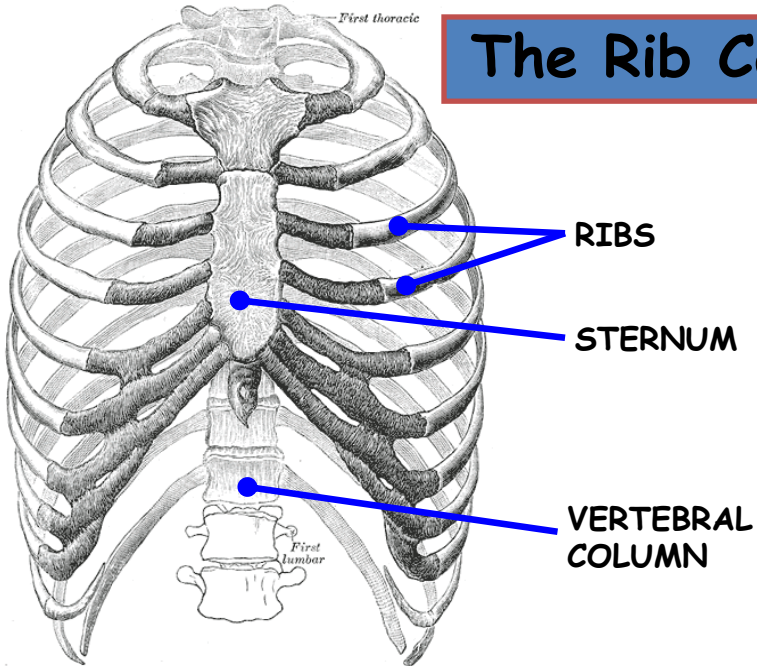
MECHANISM OF BREATHING		
	INSPIRATION	EXPIRATION
DIAPHRAGM	<i>Contracts and moves down</i>	<i>Relaxes and moves up - (natural dome shape)</i>
INTERCOSTAL MUSCLES	<i>Contract, rib cage moves up and out</i>	<i>Relax, rib cage moves down and in</i>
CHEST CAVITY	<i>Space inside increases</i>	<i>Space inside decreases</i>
AIR PRESSURE	<i>Greater outside - air is breathed in to make air pressure equal</i>	<i>Greater inside - air is breathed out to make air pressure equal</i>

RECAP

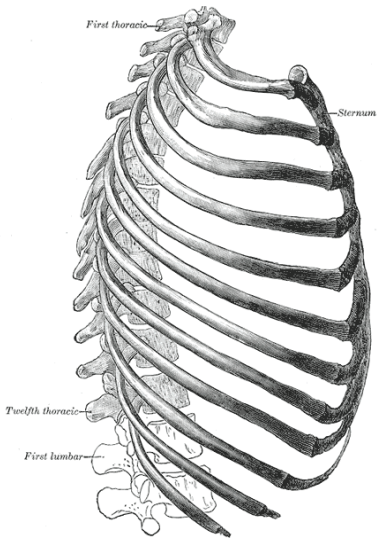
What happens during inhalation?

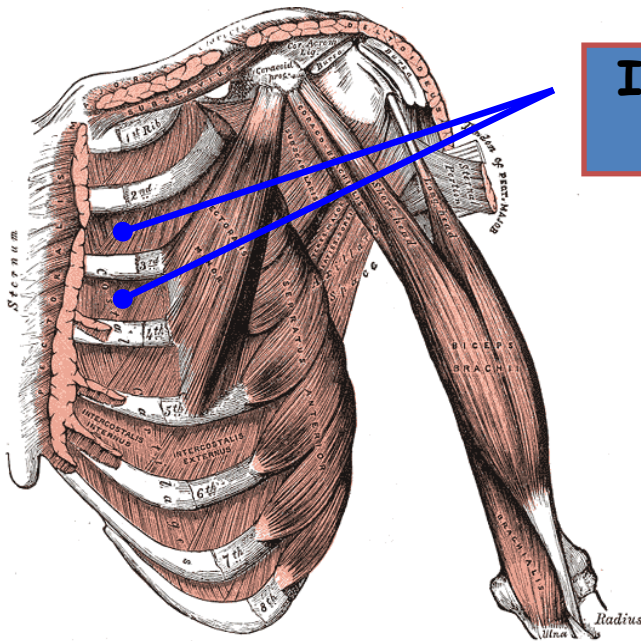
- The diaphragm flattens
- The external intercostal muscles contract
- The ribs are pulled up and outwards.
- The lungs are situated within the sealed off **THORACIC CAVITY** (chest).
- The top and sides of the TC are composed of the **ribs** that are hinged to the vertebral column at the back and to the sternum at the front, along with the muscles (**intercostal**) that lie between them.
- The floor of the TC is formed by the diaphragm a **dome shaped muscle**.

The Rib Cage

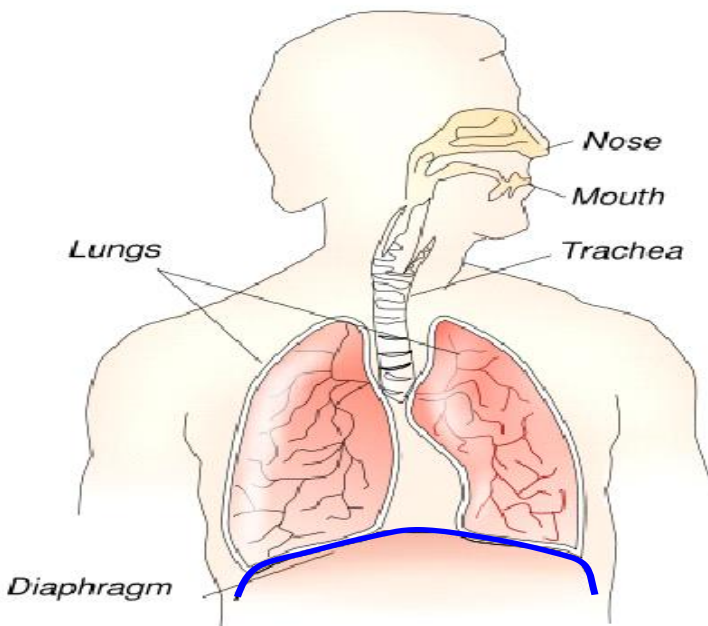


The Rib Cage Side view





Intercostal Muscles



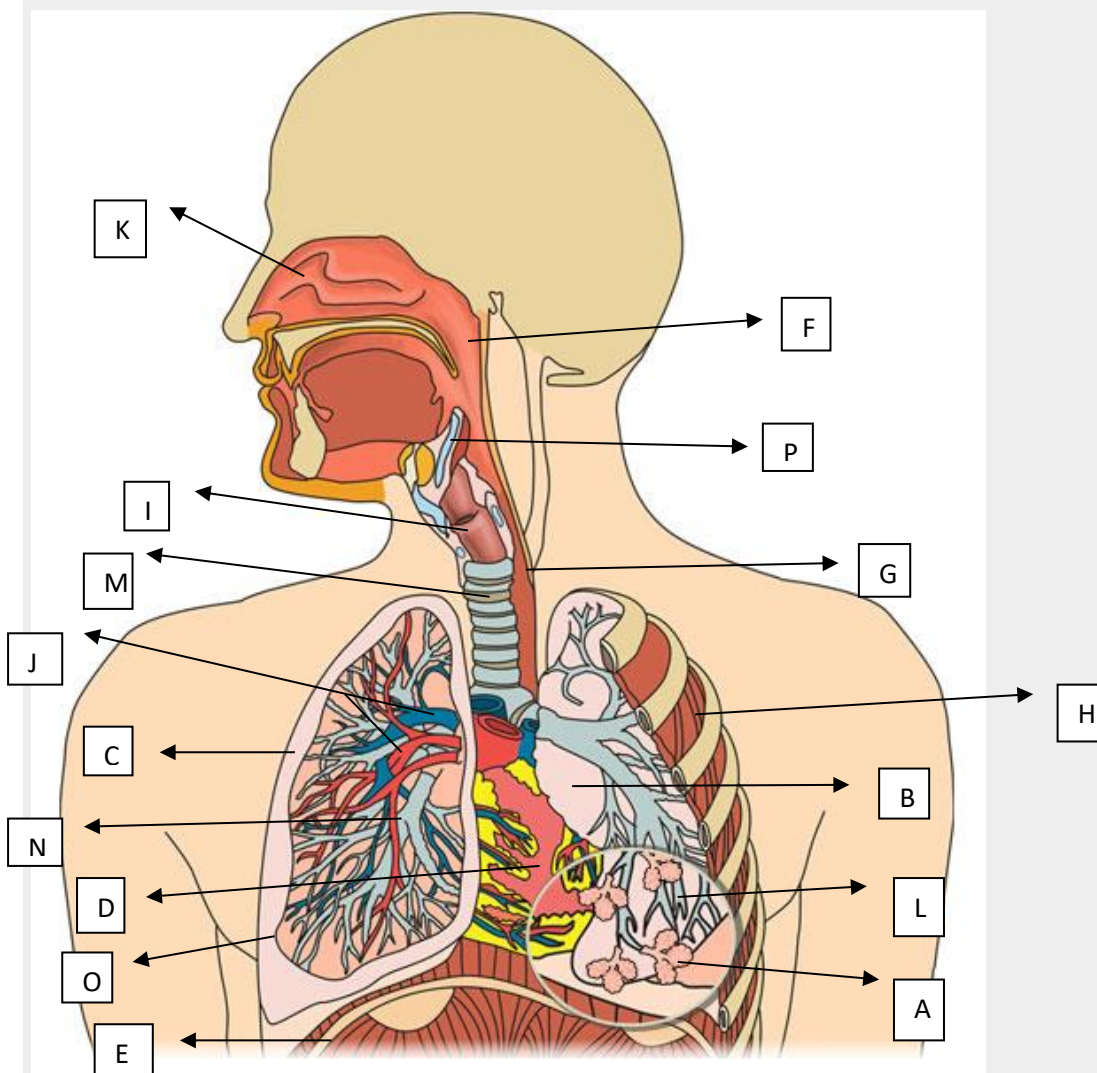
Organs of the Respiratory System

The Diaphragm - a dome shaped muscle situated on the floor of the **thoracic cavity** - aids in the mechanism of breathing in conjunction with the **intercostal muscles** between the ribs.

- When we **inhale**, air is sucked in through the **nose** and mouth, where it is **warmed** and filtered. Air then flows down the throat (**pharynx**) and then down the windpipe (**trachea**), which is held open by 16-20 C-shaped rings of hyaline **cartilage** that prevent it from collapsing.
- The trachea divides into two main **bronchi** - one goes to the left lung and the other to the right lung. The bronchi divide into smaller and smaller **branches**, the smallest of which are called **bronchioles** which have no cartilage but do contain smooth **muscle**.

- At the end of the smallest of the bronchioles are tiny air sacs called **alveoli** and each one is surrounded by a network of **capillaries**. Oxygen passes from the alveoli to the capillaries by the process of **diffusion** and carbon dioxide passes the other way, to be exhaled.
- The hundreds of **millions** of alveoli make the overall surface of the lungs very **large** allowing for the maximum amount of **oxygen** to be passed into the blood. The oxygen is **transported** in the blood to each cell in the body where it is used for cell **respiration**. Air passages are lined with ciliated epithelium tissue.

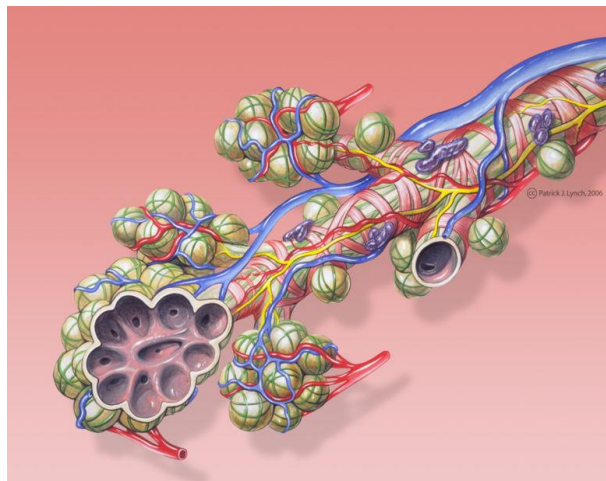
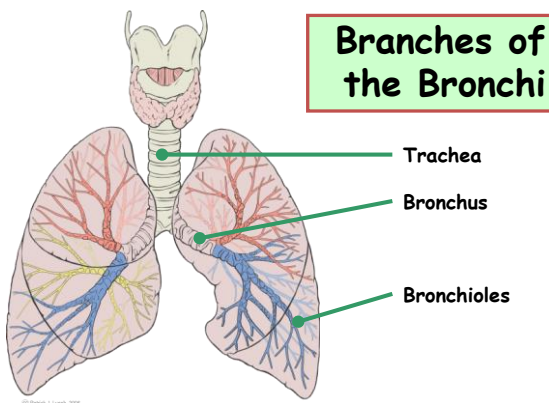
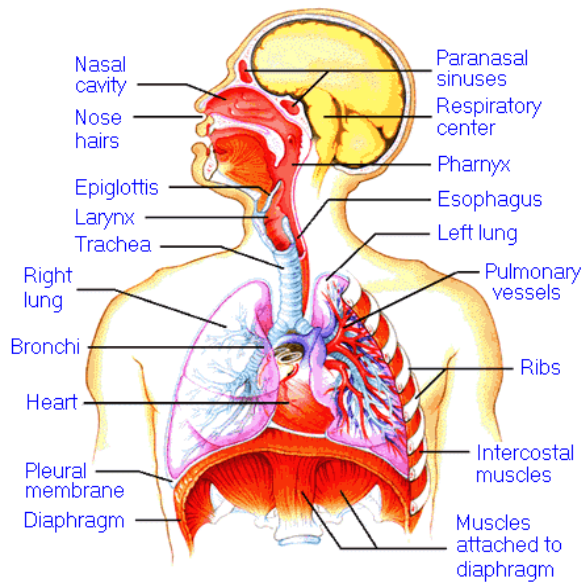
The Respiratory System

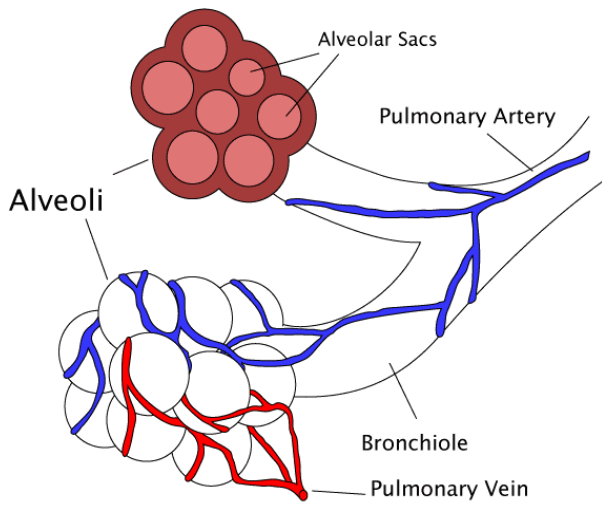


K	Nasal cavities	A	Alveoli
I	Larynx	E	Diaphragm
M	Trachea	L	Bronchioles
J	Pulmonary vessels	F	Pharynx
C	Right lung	P	Epiglottis
N	Bronchi	G	Oesophagus
D	Heart	H	Intercostals muscles
O	Pleural membrane	B	Left lung



The Respiratory System



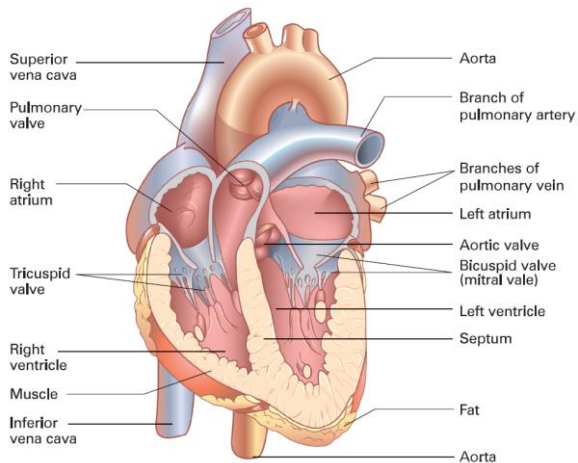


CIRCULATORY SYSTEM

Cardiovascular System

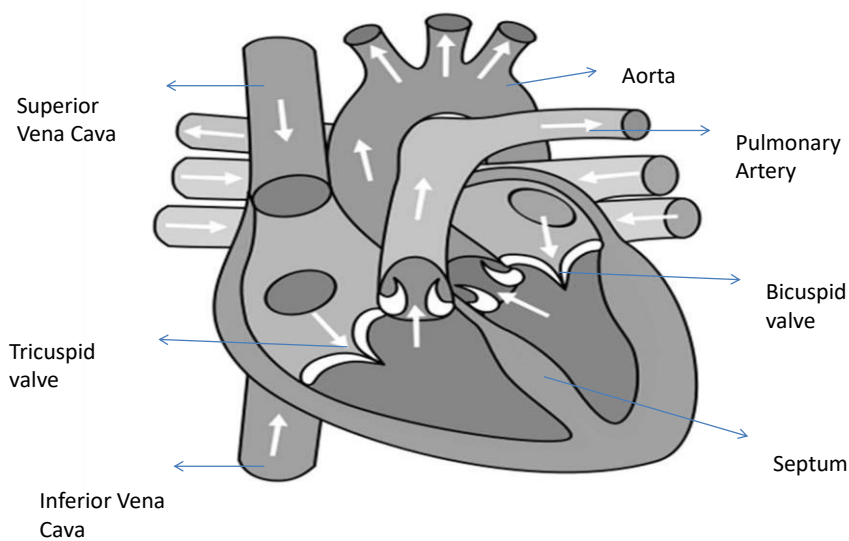
- The cardiovascular system is made up of:
- The heart
- Blood
- Blood vessels

Structure of the heart



Lashes Academy

5



Lashes Academy

4

THE HEART

- Is a hollow muscular organ 'pump' - myocardium
- Pumps blood to all the tissues around the body through a network of blood vessels.
- Comprises of 4 chambers
- Upper chambers = Atria

- Lower chambers = Ventricles
- Divided into 2 halves by the **septum**
- Left side deals with oxygenated blood
- Right side deals with de-oxygenated blood
- Situated in the thoracic cavity
- Between the lungs – slightly to the left
- Protected by the rib cage
- **The function of the heart is to act as a pump and maintain a constant circulation of blood around the body**

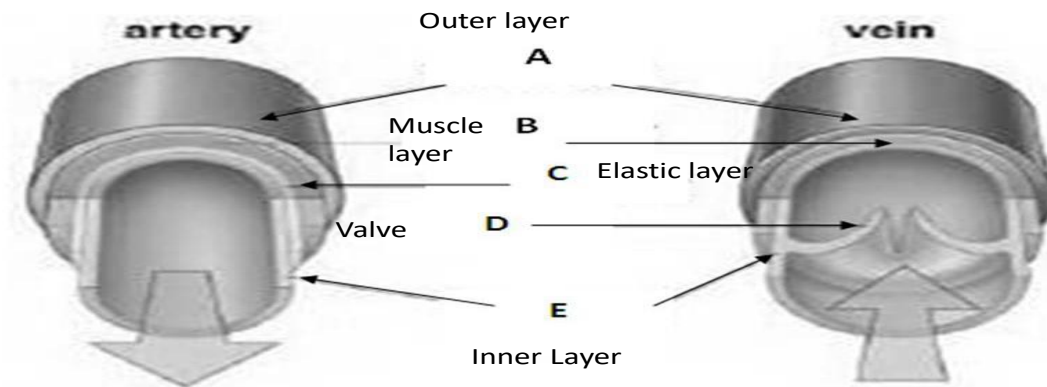
Arteries	Veins	Capillaries
Carry blood away from the heart	Carry blood towards the heart	Link arteries and veins
Carry oxygenated blood	Carry de-oxygenated blood	Tissue fluid exchange
Thick muscular, elastic walls - divide into smaller arterioles	Less thick walls - contain valves - divide into smaller venules	Walls only one cell thick to allow diffusion and has no valves.
Blood under high pressure	Blood under low pressure	Stronger on arterial side
Generally deep seated (except pulse)	Generally superficial	Form networks in tissues

Lashes Academy

7

- **The heart receives blood from the lungs by the pulmonary vein bringing oxygenated blood to the left atrium of the heart**
- **The exchange of gases in the lungs takes place between the alveoli and the pulmonary capillaries**
- **The right ventricle of the heart pumps blood to the lungs**
- **The aorta receives oxygenated blood from the left ventricle.**
- **During injury to the body, blood loss is prevented by which platelets and clotting**

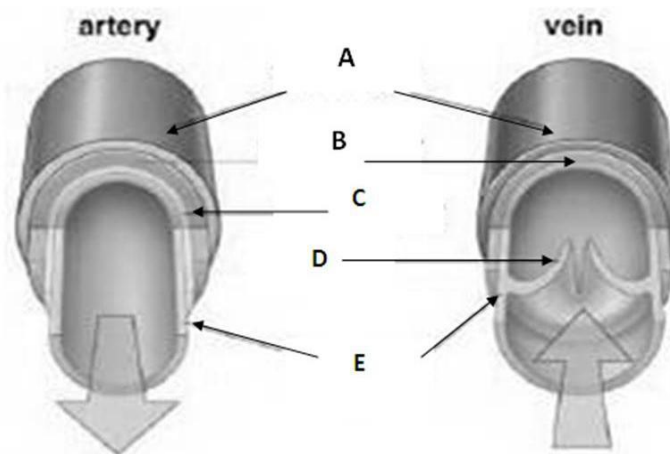
Structure of an artery & vein



Lashes Academy

8

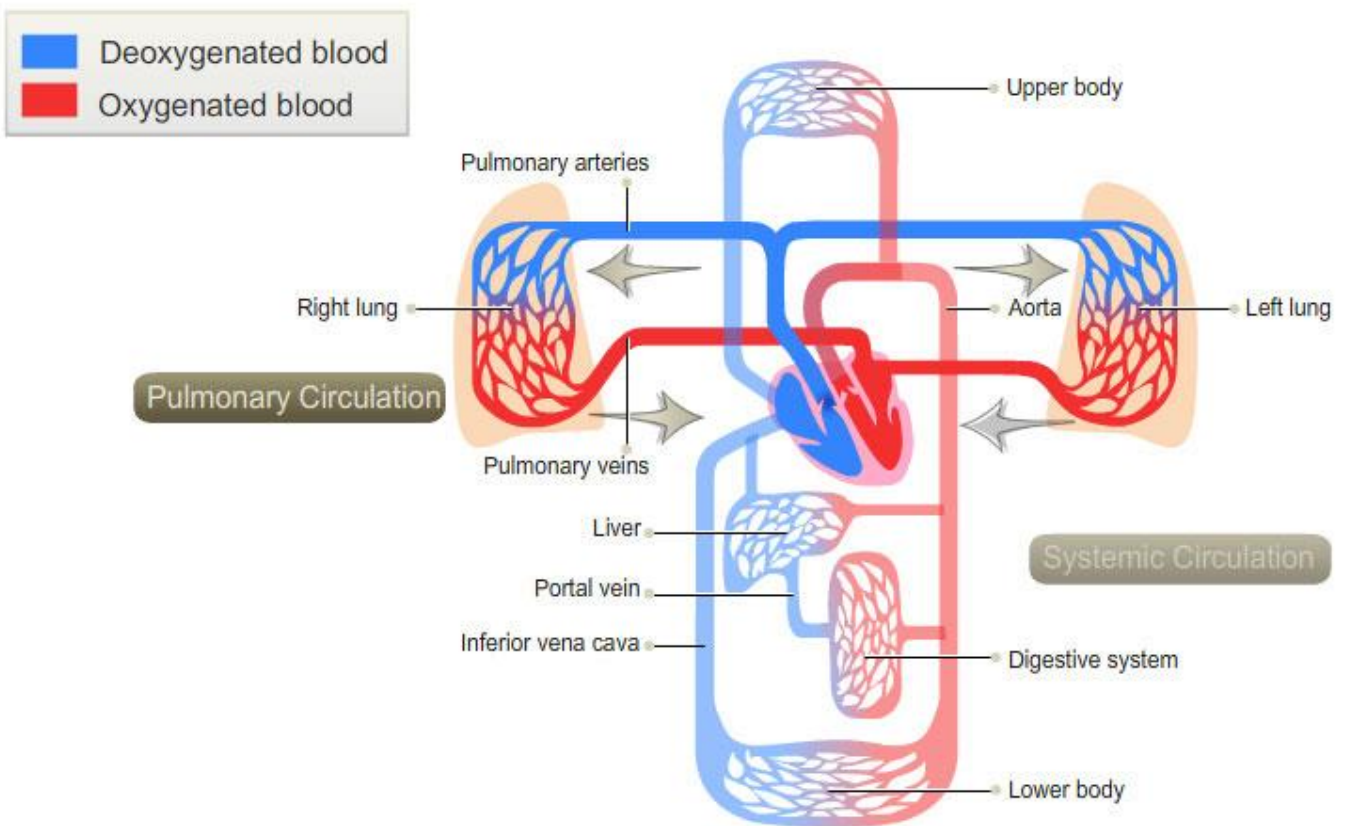
Structure of an artery & vein



D	Valve
A	Outer layer
C	Elastic layer
B	Muscle layer
E	Inner layer

Lashes Academy

11



K	Pulmonary Arteries	H	Liver
E	Lower body	D	Digestive system
C	Left lung	G	Portal Vein
A	Upper body	F	Inferior Vena Cava
B	Aorta	I	Pulmonary veins

J	Right lung		
---	------------	--	--

Pulmonary circulation

- The circulation of blood from the heart to the lungs and back.
- Deoxygenated blood travels from the heart to the lungs in the **pulmonary artery**.
- The blood gets rid of its carbon dioxide (CO₂) and replaces it with oxygen.
- It then returns to the heart via **pulmonary vein** (from lungs to heart) ready to be pumped around the body.

Systemic circulation

- Systemic circulation is the circulation of blood from the heart to the body.
- Blood leaves the heart by the **aorta**, the largest artery in the body.
- Travels throughout the body and returns to the heart through the **inferior** and **superior vena cavae** (2 of the largest veins).
- An extensive network of arteries, veins and capillaries transports blood to every cell in the body.

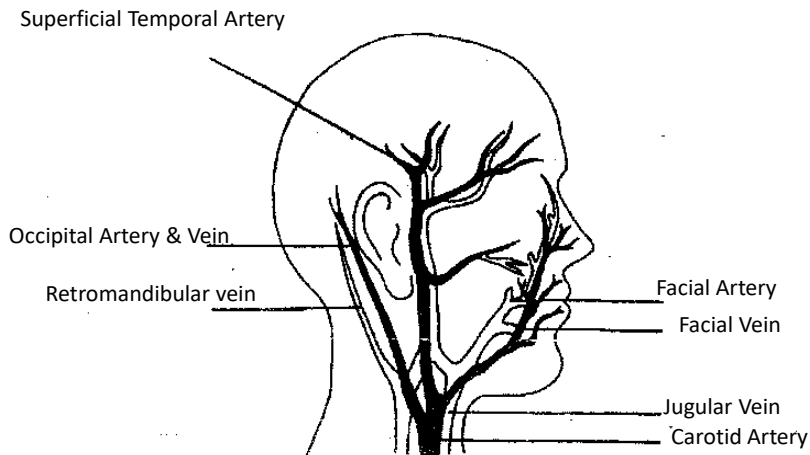
Coronary circulation

- The heart is a muscle which also needs the benefit of the circulation.
- It has its own circulatory system called coronary circulation.
- Arteries leave the beginning of the **aorta** and branch within the heart wall to form a network of capillaries which feed the tissue cells.

Portal circulation

- The veins from the stomach, spleen, pancreas and intestines join to form the **hepatic-portal** vein which carries blood into the liver.

BLOOD VESSELS OF THE HEAD & NECK



Lashes Academy

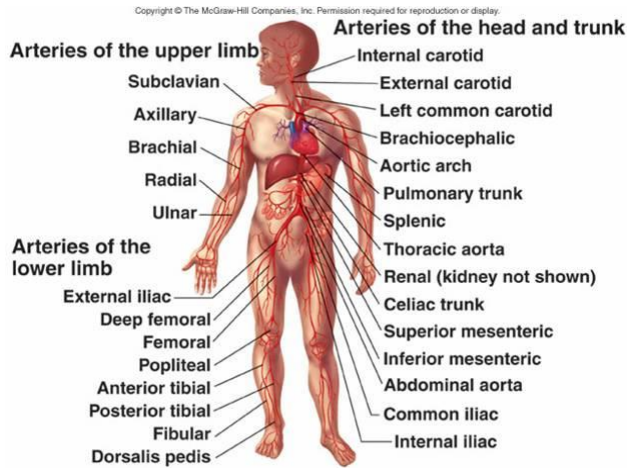
16

BLOOD SUPPLY TO THE HEAD AND NECK	
VESSEL	AREA SUPPLIED/DRAINED
Internal carotid artery	Supplies blood to brain and eyes
External carotid artery	Main vessel supplying blood to upper part of neck/face – subdivides into branches supplying other areas: <i>facial, occipital, temporal</i>
Facial artery	Supplies upper/lower and facial muscles
Superficial temporal artery	Supplies the face by its transverse (across) facial branch
Occipital artery	Supplies upper part of the neck and back of scalp
Internal jugular vein	Drains blood from brain
External jugular vein	Main vessel draining blood from face/neck – blood is supplied to it by smaller veins which drain different area
Facial vein	Drains front of scalp and superficial structures of the face
Retromandibular vein	Drains face below jaw and back of scalp

Lashes Academy

17

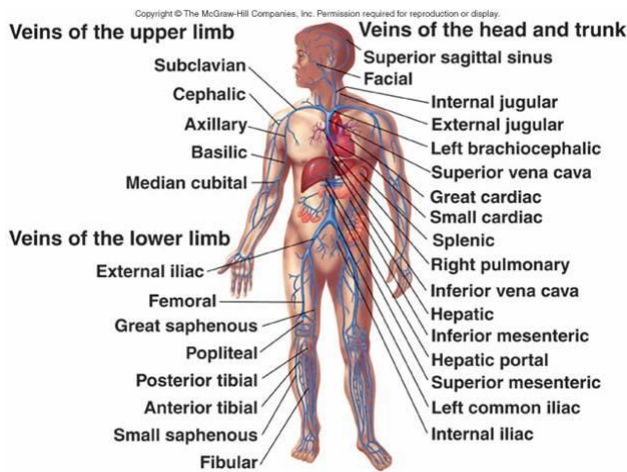
Major arteries of the body



Lashes Academy

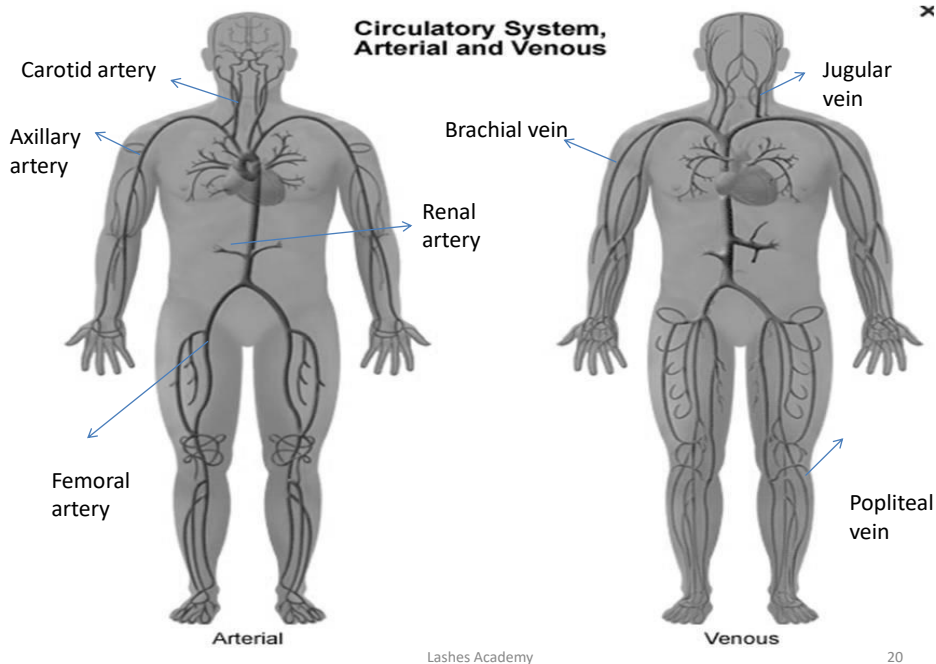
18

Major veins of the body



Lashes Academy

19



Blood

Plasma:

- Plasma makes up 55% of blood volume.
- It is a slightly thick, straw coloured fluid.
- Mostly water 90-92%
- The rest is plasma proteins (albumin, globulin, fibrinogen and prothombin).
- Plasma helps to transport the following essential substances around the body:
- Mineral salts, nutrients, waste, hormones, enzymes, gases, antibodies and antitoxins.

Leucocytes:

- Also known as white corpuscles/blood cells.
- There are two main types, granulocytes and agranulocytes.

Structure: larger than erythrocytes, with an irregular shape and a nucleus.

Function: to protect the body from infection

Erythrocytes:

- Also known as red corpuscles/ red blood cells

Structure:



- Biconcave, nucleus free discs

Function:

- Transports oxygen.

Thrombocytes

- Also known as platelets.

Structure:

- small, fragile cells with no nucleus.

Function:

- Responsible for blood clotting

Blood Pressure

- Blood pressure is the force exerted on the walls of the blood vessels.
- Blood pressure increases as blood viscosity increases.

FUNCTIONS OF BLOOD

TRANSPORT

- Red blood cells contain haemoglobin which carries oxygen from the lungs to cells of the body
- Carbon dioxide is carried from cells to the lungs
- Plasma – liquid consisting mainly of water – carries nutrients (glucose, amino acids, vitamins, minerals), gases, waste products and hormones

DEFENCE (protection)

- White blood cells digest micro-organisms (which invade the body) and help fight infection

CLOTTING

- Platelets form a clot over damaged skin, which prevents further blood loss

HEAT REGULATION

- Blood absorbs heat, which is produced by the muscles and liver and transports it around the body to maintain a constant internal temperature
- Blood helps regulate the body's pH balance

LYMPHATIC SYSTEM

The circulation of lymph is **one way**:

1. Lymph circulates away from the cells taking waste products, bacteria and foreign materials to be filtered and eliminated from the body. **The lymphatic systems help to prevent/fight infection and drains/distributes away excess fluid from the body and transports fats**; it could be likened to a one-way drainage system.

- The lymphatic system is closely connected to the blood system.
- Primary function is defensive, removing bacteria and foreign materials, thereby preventing infection.
- Also drains away excess fluids for elimination from the body.
- The lymphatic system consists of:
 - Lymph (fluid)
 - Lymph vessels
 - Lymph nodes/glands

Lymph structures

Lymph

Straw coloured fluid, derived from blood plasma. Similar composition to blood, but with less oxygen and less nutrients. Travels in one direction only; from body tissues back towards the heart. The difference between lymph and blood plasma is that lymph contains more white blood cells.

Lymphocytes

Carried in the lymph fluid, they are a type of white blood cell; they play an important role in the immune system.

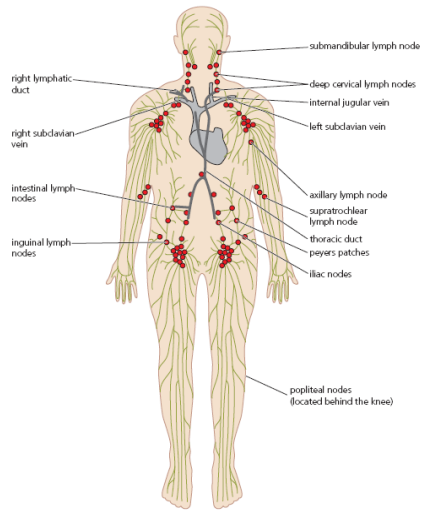
- **Capillaries** – also present in the tissue fluid, where blood capillaries are delivering oxygen and nutrients. As the walls of the lymphatic capillaries are also one cell thick, they are able to absorb the excluded blood plasma, and resulting waste products and dead cells through their walls. As soon as the excess fluid is absorbed into the lymphatic capillaries, it is also known as lymphatic fluid.
- **Vessels** – the lymphatic capillaries join together to form **lymphatic vessels which carry lymphatic fluid**. These lymphatic vessels follow the course of veins through the body, so forming an extensive network.
- The specialised lymphatic vessels in the small intestine absorb lipids.
- The spleen is the lymphatic organ that curves around the stomach.

- The body's ability to remember and recognise antigens that have triggered an immune response is known as acquired immunity.
- **Nodes** – along the course of these vessels are tiny oval structures called nodes. These are bean-shaped structures covered in a capsule of connective tissue. These act as filtering points for lymph and it is where harmful substances, pus and bacteria are filtered out, destroyed and/or engulfed. Special cells, called lymphocytes, release antibodies into the lymph, so helping us to resist invasion of micro-organisms and, so, preventing disease.
- **Ducts** – as the lymphatic vessels join up to form larger vessels, they eventually flow into one of two main, large lymphatic vessels called the thoracic duct and the right lymphatic duct. It is these ducts that the filtered lymph is drained back into the blood circulation, via the subclavian veins.
- **Thoracic duct** – largest of the two ducts situated down the centre of the body that collects lymph from the left side of the head and chest, the left arm, both legs and the abdominal and pelvic areas of the body. The thoracic duct then drains the lymph into the left subclavian vein.
- **Right lymphatic duct** – small duct situated at the base of the neck that collects lymph from the right side of the head and chest and the right arm. The right lymphatic duct then drains the lymph into the right subclavian vein.
- Once the filtered lymph re-enters the blood circulatory system, it becomes part of the blood plasma of the deoxygenated blood. Through the subclavian veins, the blood travels to the vena cava, the main vessel that returns blood to the heart. Courtesy of oxygen being introduced to the blood via the lungs, the oxygenated blood can now start its next circuit around the body, to start the whole process again.
- **The main lymph nodes located in the arm are axillary and supratrochlear.**

Defence:

- Lymph nodes provide a filtering system helping the body defend itself by filtering out bacteria from the lymph within the lymph nodes.
- Special cells, called lymphocytes, release antibodies into the lymph, so helping us to resist invasion of micro-organisms and, so preventing disease.
- The body's ability to remember and recognise antigens that have triggered an immune response is known as acquired immunity.

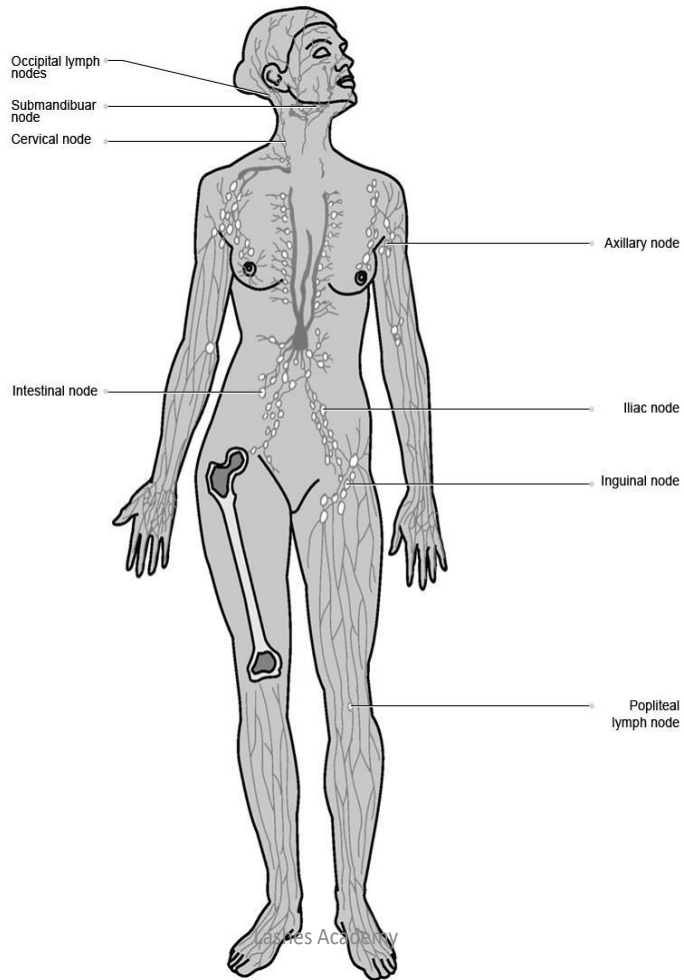
Lymph vessels and nodes (glands) of the body



Lymph vessels and nodes (glands) in the body

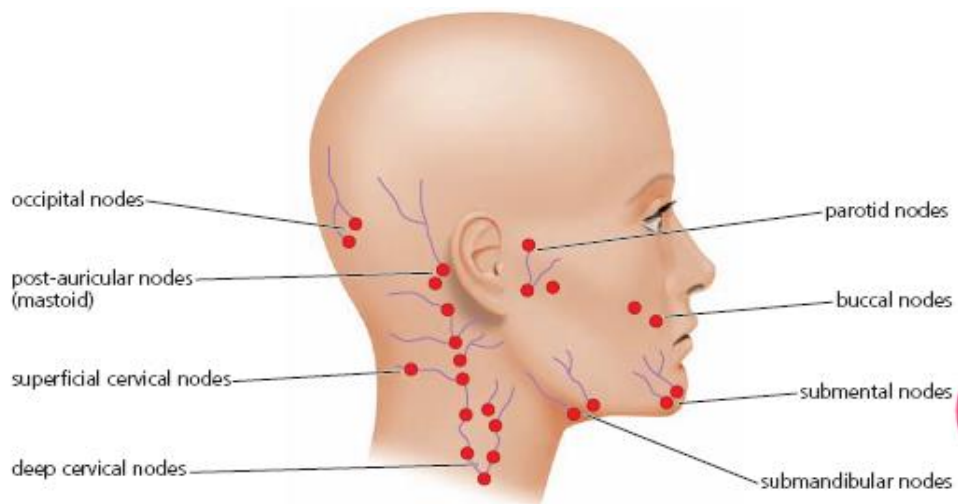
Lashes Academy

11



NAME	LOCATION
OCCIPITAL NODES	The occipital lymph nodes are located at the back of the head. They are specifically located near a muscle, at the point where the head and neck meet. Like other lymph nodes, these occipital nodes take in lymph fluid to filter out harmful cells or particles. By virtue of their location, the lymph that passes through them is the one that has gone around the scalp.
CERVICAL NODES	The cervical nodes are located in the chest region. These nodes are arranged lower jaw border, around the front and back of the ears, and deep in the neck area amongst the larger blood vessels. They help drain the skin of the face, scalp, nasal cavity tissues and the pharynx.
INGUINAL NODES	Inguinal nodes are located in the legs and groin and receive lymph from the legs, the outer part of the genitalia and the lower abdominal wall;
SUBMANDIBULAR NODES	The submandibular nodes can be found between the mandible and the submandibular gland. They receive lymph from vessels on the face below the eye and the tongue and drain into the superior deep cervical nodes.
POPLITEAL NODES	Very small popliteal lymph nodes are located in the legs. Most of them can be found embedded in the fat of the popliteal fossa.
AXILLARY LYMPH NODES	In the axillary region, the lymph nodes are located in the underarm region. They receive lymph from vessels that drain the breast, arm, thorax walls, and the abdomen upper walls.

Lymph nodes of the head



Lymph nodes of the head and neck

LYMPH SUPPLY TO THE HEAD AND NECK

NODES/DUCT/VESSEL	AREA DRAINED
Submental Nodes	Drain lymph from chin
Submandibular Nodes	Drain lymph from middle of cheeks
Parotid Nodes	Drain lymph from sides of cheeks and forehead
Thoracic Duct	Main collecting duct – collects lymph from left side of head and neck, left arm, lower limbs and abdomen.
Left Subclavian Vein	Lymph from thoracic duct drains into this vein
Right Lymphatic Duct	Very short in length – collects lymph from right side of head and neck and right arm
Right Subclavian Vein	Lymph from right lymphatic duct drains into this vein
Cervical Nodes	drains the back of head, neck & scalp

DIGESTIVE SYSTEM

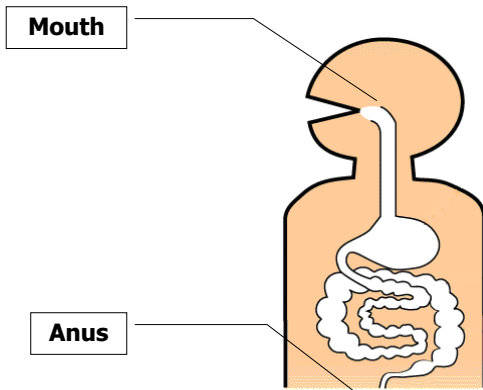
The digestive system is known as the **alimentary canal**. Most foodstuffs such as carbohydrates, fats and proteins need digesting. Minerals and some vitamins do not need digesting.

Digestion starts at the mouth where food is broken down **mechanically** by the teeth and then **chemically** by the body's digestive juices so that it can be absorbed and used by the body's cells and ends at the large intestine.

The functions of the digestive system include mastication, ingestion, digestion, absorption and defecation. elimination of food

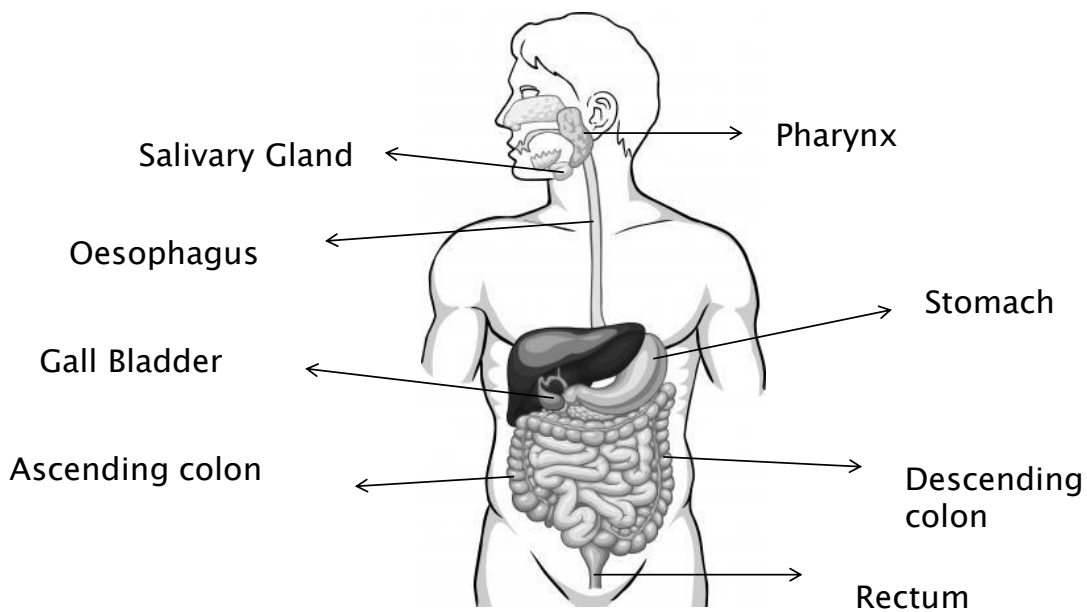
- ▶ The digestive tract, also called the **Alimentary canal** or Gastrointestinal (GI) tract.
- ▶ This consists of a long continuous tube that starts at the mouth and finishes at the anus.
- ▶ **It includes the mouth, pharynx, oesophagus, stomach, small intestine (duodenum, jejunum, ileum, and large intestine (colon), colon, rectum and anus.**
- ▶ Digestion takes place as the food passes along a long tube.

Alimentary canal



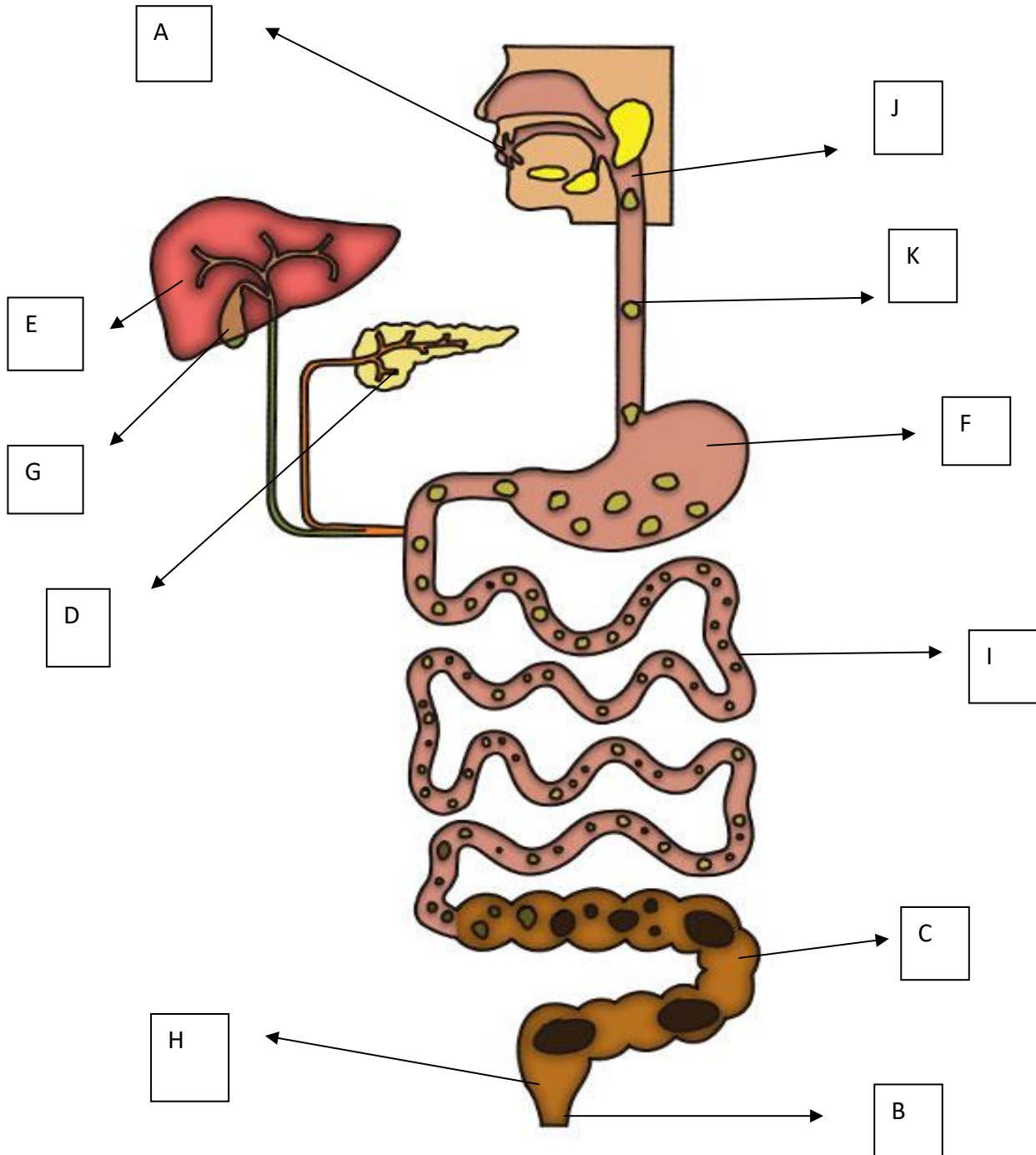
Lashes Academy

4



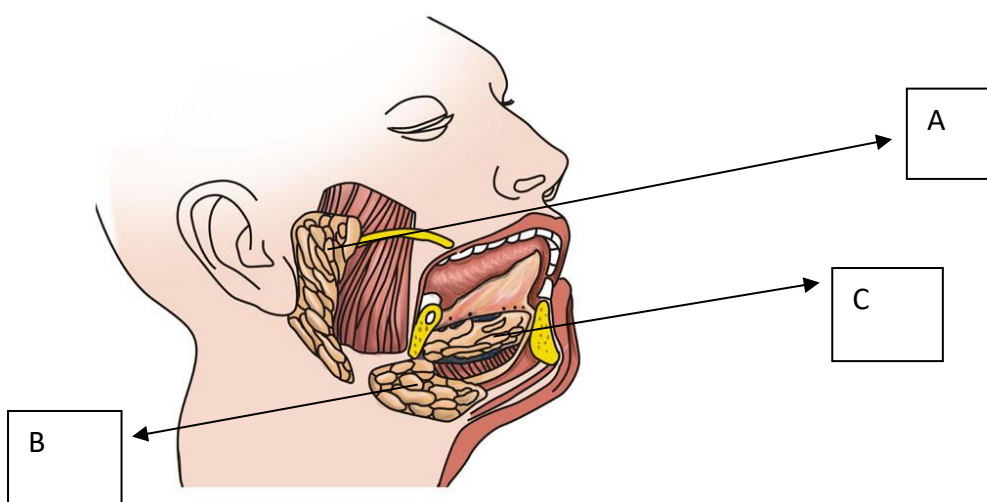
Lashes Academy

6



1	A	Mouth	7	G	Gallbladder
2	B	Rectum	8	H	Anal canal
3	C	Large intestine	9	I	Small intestine
4	D	Pancreas	10	J	Pharynx
5	E	Liver	11	K	Oesophagus
6	F	Stomach			

SALIVARY GLANDS – PLEASE LABEL DIAGRAM



1	A	Parotid gland
2	C	Sublingual gland
3	B	Submandibular gland

There are three major salivary glands that are arranged in pairs, called the parotid, sublingual and submandibular glands. They primarily produce the saliva which moistens the mouth.

The parotid gland is located near the ear; the sublingual gland is located beneath the tongue and above the submandibular gland which is located in the floor of the mouth.

Saliva contains a digestive enzyme, called amylase, which is brought into the mouth via ducts. Saliva enables food to be moistened and dissolved and makes chewing and swallowing much easier.

Mouth

- ▶ Teeth cut up the food - mechanical digestion
- ▶ Salivary glands release saliva to moisten and hold the cut food together
- ▶ Food is rolled into a ball (bolus) before swallowing

Swallowing

- ▶ Swallowing is a reflex action caused by the food pushing against the soft palette
- ▶ The food passes down the pharynx
- ▶ The epiglottis seals the top of the trachea to prevent food entering the wind pipe
- ▶ The food passes into the oesophagus

Oesophagus

- ▶ Transports the food from the pharynx to the stomach
- ▶ Food is pushed down the oesophagus by peristalsis
- ▶ Peristalsis is the squeezing movement produced by layers of smooth muscle
- ▶ Produces a wave of contraction which moves food the food down the tube

The Stomach

- ▶ The stomach is a pouch J shaped organ under the liver and diaphragm.
- ▶ Food can stay in the stomach for 1-4 hours where it is mixed by muscular contractions of the stomach walls which liquefies the food
- ▶ Some absorption of fluid does take place in the stomach.
- ▶ Layers of muscle contract, to churn and break up the food (mechanical digestion) into a liquid known as Chyme.

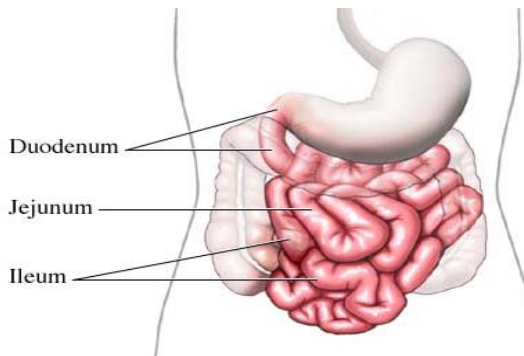
Functions of the Stomach

- ▶ Mechanical breakdown of food
- ▶ The breakdown of carbohydrates starts in the mouth.
- ▶ Start of digestion of proteins by enzymes
- ▶ Some absorption of fluid
- ▶ Passage of Chyme to duodenum

Small Intestines

Consists of 3 sections;

- ▶ Duodenum- Connects to the stomach
- ▶ Jejunum- The middle portion
- ▶ Ileum- Attaches to the large intestine



Duodenum

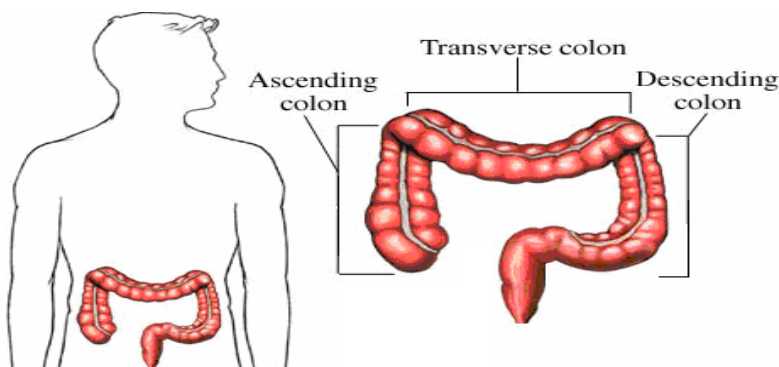
- ▶ Walls release a strong alkali to neutralise the acid Chyme from the stomach.
- ▶ The walls of the duodenum release enzymes (Chemical digestion). Pepsinogen breaks down proteins.
- ▶ The enzymes continue to break down the food as it passes along the duodenum and Jejunum by peristalsis.

Ileum

- ▶ The walls of the ileum release further enzymes to break down the food to its simple substances as it passes along by peristalsis Before emptying into the large intestine
- ▶ As chemical digestion takes place in small intestines so does absorption
- ▶ The end products of digestion are absorbed through the walls of the small intestines and into the surrounding blood capillaries
- ▶ Most fats are absorbed not by blood capillaries, but into lymph capillaries via lacteals and are transported to the blood in the lymphatic system.

Large Intestine

- ▶ Also known as the Colon. The large intestine has 3 sections



- ▶ Undigested food and water pass from the small intestines into the large intestines
- ▶ As this liquid waste passes through the colon water is reabsorbed back into the blood
- ▶ This causes the waste to become more solid

Rectum

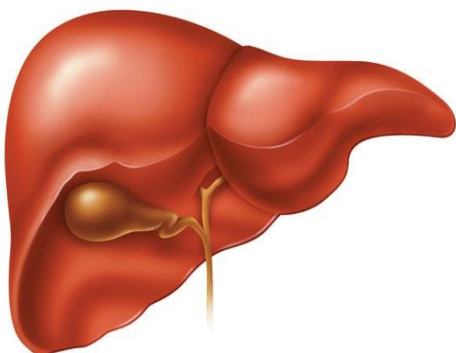
- ▶ The waste, (faeces) consists of remnants of fibre, undigested materials and bacteria, passes into the rectum
- ▶ Here it is stored, until it is removed (eliminated) from the body via the anus

Accessory structures/organs

- ▶ The tongue and teeth are accessory structures located in the mouth.
- ▶ The salivary glands, liver, gallbladder, and pancreas are major accessory organs that have a role in digestion.
- ▶ These organs secrete fluids into the digestive tract.

Liver

- ▶ Produces bile
- ▶ Sends it to gall bladder for storage

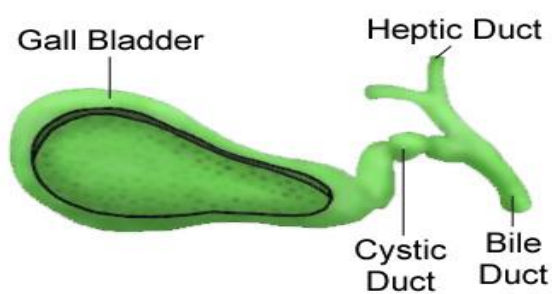


- ▶ As well as producing bile the liver has a number of other jobs
- ▶ **Controlling the amount of glucose in the blood and maintains normal blood glucose levels**
- ▶ Storing glucose as glycogen
- ▶ Regulating the amino acids in the blood

- ▶ Converting excess amino acids to glucose and urea (waste product)
- ▶ Storing vitamins and iron
- ▶

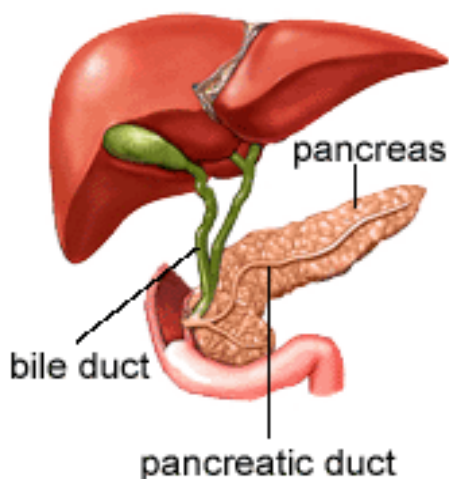
Gall bladder

- ▶ Stores bile
- ▶ Releases bile into duodenum through bile duct



The Pancreas

- ▶ This gland has an exocrine portion that secretes digestive pancreatic enzymes.
- ▶ They flow into the main pancreatic duct.
- ▶ This duct joins the common bile duct, which connects the pancreas to the liver and the gallbladder.



Digestive system

Organ	secretion
Mouth Salivary glands	Salivary amylase
Stomach	Rennin Hydrochloric acid Pepsin
Duodenum	1. Pancreatic juice • Trypsin • Lipase • Amylase • Bile 2. Bile
Small intestine	Intestinal juice • Maltase • Sucrase • Lactase

Lashes Academy

27

Be able to have knowledge of further career pathways

Some examples:

A trichologist is someone who can advise and diagnose a wide range of disorders of the scalp and hair

A dermatologist is a person who deals with the diagnosis and treatment of diseases related to skin, hair and nails

Other examples:

Advanced beauty therapy

body massage

reflexology

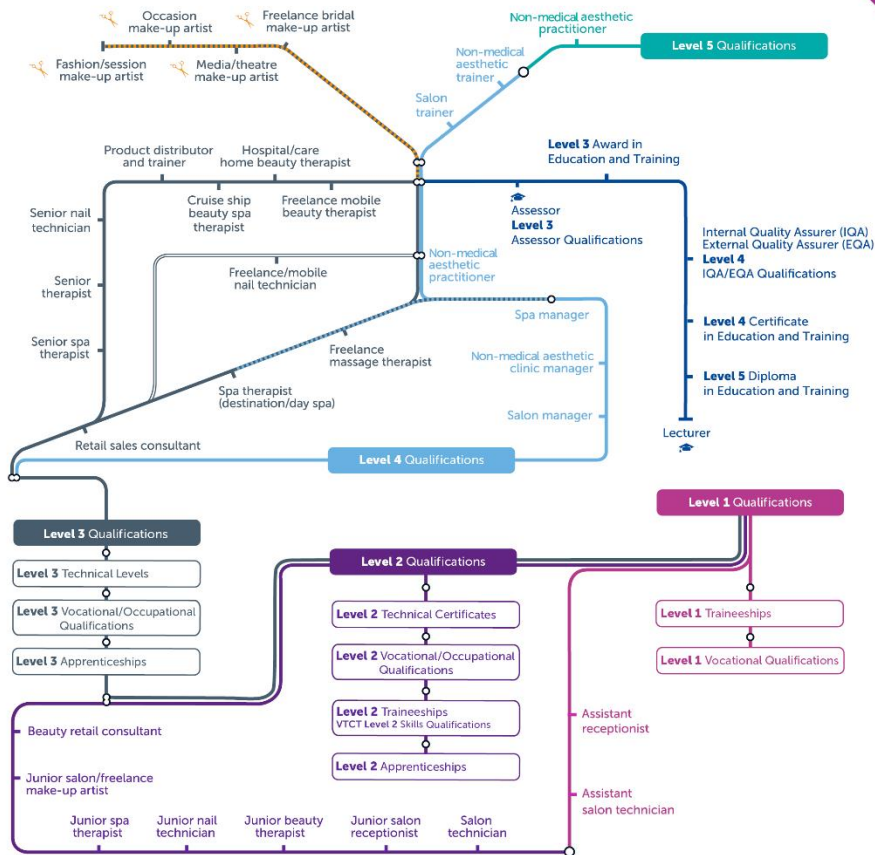
aromatherapy

spa therapy

quality management.

You need to research three of the above and write information.

Beauty, Nails & Spa Career Paths



- Key**
- Level 1 Beauty, Nail & Spa Therapy route
 - Level 2 Beauty therapy, make-up, nails route
 - Level 3 Beauty therapy route
 - Level 3 Nails route
 - Level 3 Make-up route
 - Level 3 Spa therapy or massage route
 - Level 4 Beauty & Spa Therapy route
 - Level 5 Advanced Aesthetics Route
 - Progression qualifications
 - Education & Training sector
 - Combined Hairdressing & Beauty sector

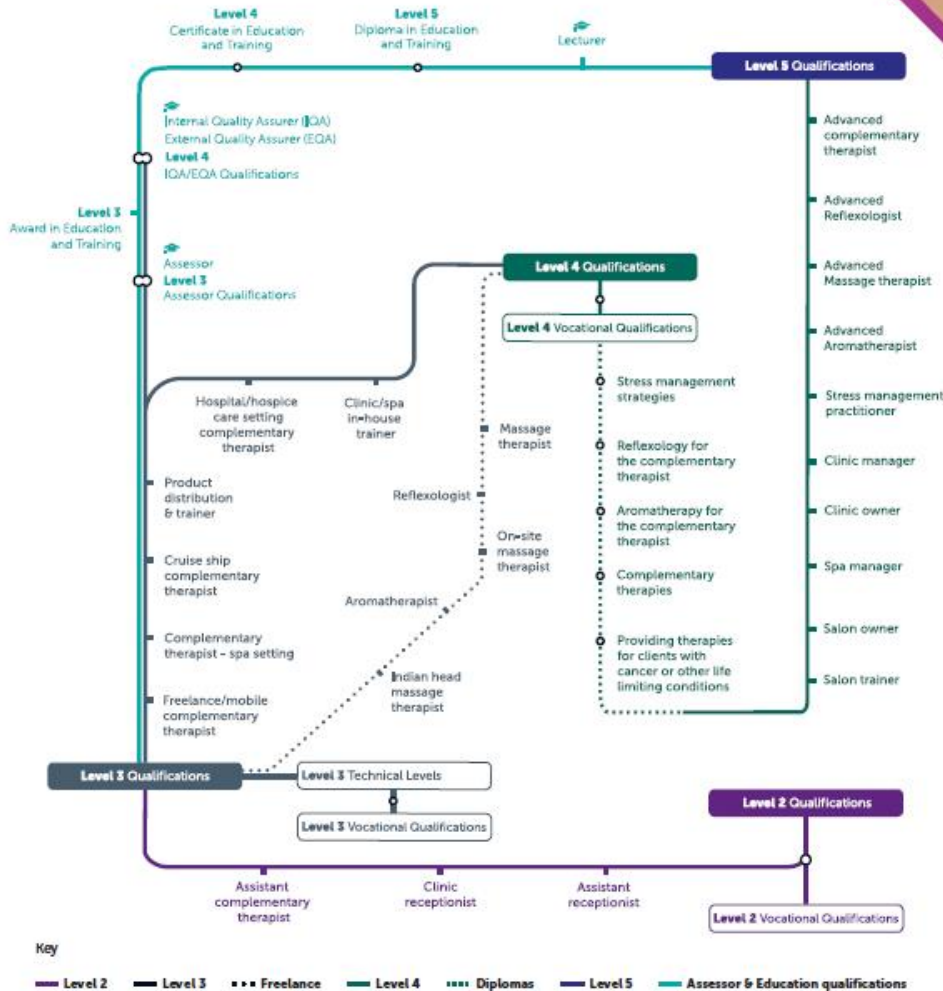
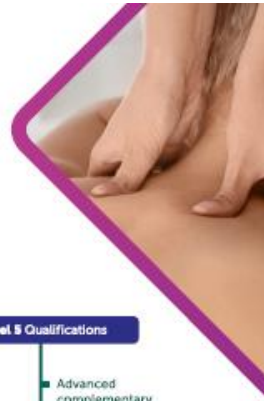

Smarter support for brighter futures

www.vtct.org.uk

© 2019 VTCT

Complementary Therapy Career Paths



Smarter support for brighter futures

www.vtct.org.uk

© 2019 VTCT

